



Extracorporeal shock wave therapy (ESWT) for wound healing: Technology, mechanisms, and clinical efficacy

Rainer Mittermayr, MD^{1,2}; Vlado Antonic, MS^{5,6}; Joachim Hartinger¹; Hanna Kaufmann, MD³; Heinz Redl, PhD¹; Luc Téot, MD, PhD⁴; Alexander Stojadinovic, MD⁵; Wolfgang Schaden, MD²

1. Ludwig Boltzmann Institute for Experimental and Clinical Traumatology, Austrian Cluster for Tissue Regeneration, Vienna, Austria,
2. AUVA Trauma Center Meidling, Vienna, Austria,
3. Difficult Wound Healing Unit, Maccabi Health Services and Rambam Healthcare Campus, Haifa, Israel,
4. Burns Unit, Wound Healing Unit, Lapeyronie Hospital, Montpellier University Hospital, Montpellier, France,
5. Combat Wound Initiative Program, Washington, DC, and
6. Henry M Jackson Foundation for the Advancement of Military Medicine, Bethesda, Maryland

Reprint requests:

Dr. Rainer Mittermayr, Ludwig Boltzmann Institute for Experimental and Clinical Traumatology, Austrian Cluster for Tissue Regeneration, Donauschtingenstrasse 13, A-1200 Vienna, Austria.
Tel: +43 133110464;
Fax: +43 133110460;
Email: rainer.mittermayr@trauma.lbg.ac.at

Manuscript received: July 19, 2011
Accepted in final form: February 29, 2012

DOI:10.1111/j.1524-475X.2012.00796.x

ABSTRACT

For almost 30 years, extracorporeal shock wave therapy has been clinically implemented as an effective treatment to disintegrate urinary stones. This technology has also emerged as an effective noninvasive treatment modality for several orthopedic and traumatic indications including problematic soft tissue wounds. Delayed/nonhealing or chronic wounds constitute a burden for each patient affected, significantly impairing quality of life. Intensive wound care is required, and this places an enormous burden on society in terms of lost productivity and healthcare costs. Therefore, cost-effective, noninvasive, and efficacious treatments are imperative to achieve both (accelerated and complete) healing of problematic wounds and reduce treatment-related costs. Several experimental and clinical studies show efficacy for extracorporeal shock wave therapy as means to accelerate tissue repair and regeneration in various wounds. However, the biomolecular mechanism by which this treatment modality exerts its therapeutic effects remains unclear. Potential mechanisms, which are discussed herein, include initial neovascularization with ensuing durable and functional angiogenesis. Furthermore, recruitment of mesenchymal stem cells, stimulated cell proliferation and differentiation, and anti-inflammatory and antimicrobial effects as well as suppression of nociception are considered important facets of the biological responses to therapeutic shock waves. This review aims to provide an overview of shock wave therapy, its history and development as well as its current place in clinical practice. Recent research advances are discussed emphasizing the role of extracorporeal shock wave therapy in soft tissue wound healing.

The influence of shock waves on biological (human) tissue was first documented on castaways who were exposed to water bomb explosions during World War II. They suffered severe lung injuries but showed no overt clinical signs of traumatic injury.¹ Approximately 40 years later, in 1980, high-energy focused extracorporeal shock waves were first clinically introduced in Munich, Germany, to disintegrate urinary stones (i.e., lithotripsy). Over the ensuing 15 years, more than 2 million patients with nephro-ureterolithiasis were successfully treated with shock waves, with few treatment-related side effects.^{2,3} Hence, lithotripsy by means of extracorporeal shock wave therapy (ESWT) became the gold standard for the initial treatment of urolithiasis.^{4,5}

During the early years of medical application in the 1980s incidental experimental observations showed shock waves to have osteogenic potential. Animal experiments showed stimulated fracture healing, and histological investigations confirmed the influence of shock waves on the activation of osteoblasts with associated increased bone density.^{6,7} In 1988,

Valchanou and Michailov⁸ performed the first high-energy shock wave application with a lithotripter for delayed and nonunion fractures, and they reported an 85% success (fracture union) rate. In the years following this clinical breakthrough, shock waves were increasingly used in patients suffering from pseudarthrosis.^{7,9,10} However, devices designed for the requirements of lithotripsy were used and not specific to orthopedic indications. These initial human applications to orthopedic problems with urologic lithotripters proved to be laborious; therefore, shock wave devices specifically designed for orthopedic and traumatic indications were developed (the first orthopedic device, OssaTron [HMT AG, Lengwil, Switzerland] became available in 1993). Through the application of these modified devices, high-energy focused ESWT of delayed or nonunion fractures became the standard method of treatment in selected countries¹⁰ and slowly became the treatment of first choice.¹¹

Around the same time, at the beginning of the 1990s, the first reports about high-energy focused shock wave therapy

for calcific tendinopathy of the shoulder were published.^{12,13} Further investigations and clinical trials using ESWT had shown clinical efficacy for therapeutic shock waves for a variety of orthopedic pathologies including calcific tendonitis of the rotator cuff, lateral epicondylitis of the elbow, plantar fasciitis, achillodynia, and calcaneal spurs.^{7,14,15} In October 2000, the Food and Drug Administration approved ESWT (OssaTron device) for chronic plantar fasciitis and in 2003 for chronic lateral epicondylitis (tennis elbow).^{16–18}

In order to stay current with the emerging medical indications for shock wave therapy, accompanied by the increasing popularity and acceptance of ESWT worldwide, the European Society of Shockwave Therapy was renamed the International Society for Medical Shockwave Treatment (ISMST) in 2000, and the scope of the ISMST expanded to include all of the various clinical indications for therapeutic shock waves in 2009.

First investigations of shock waves on wound healing were undertaken in 1986.¹⁹ However, systematic studies (experimental *in vitro* and *in vivo* studies and clinical trials) evaluating the efficacy of low-energy defocused shock wave therapy on delayed healing or chronic wounds have only been performed in recent years.

To date, ESWT has become increasingly popular and become accepted worldwide. Successful application has been reported in the peer-reviewed literature for numerous medical indications. Despite this encouraging progress, the biomolecular mechanisms by which shock waves exert their positive clinical effects are yet to be completely understood. Advantages of extracorporeal shock wave therapy include: (1) non-invasiveness (avoidance of surgery); (2) low associated complication rates (e.g., minimal petechial skin hemorrhage and hematoma); (3) efficacy for indications refractory to other standards of practice (e.g., osseous non-union); (4) flat learning curve; and (5) cost-effectiveness.

This review focuses on the use of ESWT in wound healing and addresses issues related to its underlying mechanism in this field.

RELEVANCE OF ESWT IN WOUND HEALING

The incidence of chronic wounds continues to rise worldwide and constitutes an extraordinary burden not only on patients' quality of life but also on healthcare costs.²⁰ Chronic wounds are defined as wounds that have not proceeded through orderly and timely phase of tissue repair in order to reconstitute anatomic and functional integrity after 3 months.²¹ In the majority of cases, the etiology is multifaceted and includes local (e.g., venous or arterial insufficiency, infection, and local pressure) and systemic (e.g., diabetes and nutritional status) factors.

The therapeutic approach to chronic wounds (e.g., venous ulcers, diabetic ulcers, and pressure sores) up to now has been limited in both viable treatment options as well as therapeutic efficacy. Clinical standards of practice include adequate wound bed preparation with surgical and nonsurgical (e.g., enzymatic) debridement,^{22–25} application of specialized dressings²⁶ providing the wound with a moist environment,^{22,27–29} and medical or surgical intervention to attain adequate vascular inflow and outflow and sufficient offloading to avoid pressure necrosis.^{30,31} Additionally, many adjunctive therapies

have been designed for the care of chronic wounds such as negative pressure wound therapy, hyperbaric oxygen therapy (HBOT), and ultrasound.^{32–36} Several experimental approaches are currently being evaluated to further improve chronic wound care. Studies suggest efficacy using gene therapy, recombinant growth factor application, bioengineered skin (tissue engineering), and stem cell therapy.^{27,37,38} However, these (experimental) treatment approaches primarily target only a single aspect of the complex mechanism of pathological wound healing processes.

Nevertheless, treatment of chronic wounds is disproportionately prolonged and often insufficient, amounting to refractory wounds despite multimodal treatment approaches. Patient discomfort and impaired quality of life combined with enormous healthcare expenses make chronic wounds the subject of intensive research. Alternative (effective) treatment options are highly desirable to reduce both the patients suffering with chronic wound as well costs to society.

BASICS OF SHOCK WAVE TECHNOLOGY

Shock waves are transient short-term acoustic pulses with high peak pressure and a very short rise to peak pressure time on the order of magnitude of nanoseconds (one billionth of a second). Shock waves for use in medicine can be generated using different physical principles. The electro-hydraulic shock wave generation principle uses a supersonic flow to generate a shock wave within a metal enclosure that has a suitable shape to reflect the generated shock waves toward the therapeutic target with the desired wave characteristics (wave length, frequency, and amplitude). The shock wave is generated by a high voltage discharge on the electrode placed in the water-containing compartment causing the expansion of the generated plasma bubble at supersonic speed. The expansion velocity of the bubble is decelerated by the surrounding water and, at sound velocity, a shock wave front detaches from the bubble surface traveling through the water. A metallic half-ellipsoid-shaped reflector focuses the almost spherical acoustic impulse front, which has been generated in the first focal point of the ellipsoid, to a second focal point (therapeutic target). The new soft-focused applicators use a parabolic reflector capable of generating an almost parallel shock wave front (Figure 1) with a diameter the size of the reflector in order to apply the shock waves to a larger area (i.e., low-energy defocused shock wave therapy utilized for soft tissue wounds). The energy flux density of the soft-focused shock waves used for wounds is lower than that of the focused shock waves typically used for lithotripsy and delayed union or orthopedic nonunion.

Shock waves are usually characterized by a multiplicity of physical parameters. The most important parameter is the peak pressure vs. time plot where the time dependence of the transient pressure is measured using fast high-resolution pressure probes such as fiber-optic laser hydrophones. The maximum pressure of medical shock wave devices is up to 100 megapascal (MPa), one thousand times that of surrounding air pressure. A typical shape of the -6dB zone is a cigar-like distribution with a diameter of several millimeters and a length of up to 10 cm (Figure 2). The size of the therapeutic target zone is highly dependent on the shock wave source and reflector geometry leaving a wide range of possible shapes.

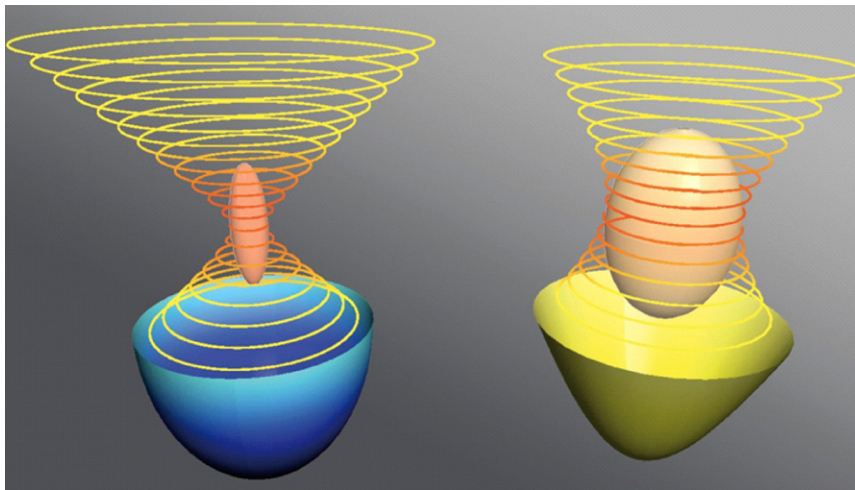


Figure 1. Electro-hydraulic shock wave field of an ellipsoidal reflector (blue) and a roughly parabolic reflector (yellow) with resulting focal zones. The resulting areas of highest intensity show cigar-like and ovoid shapes, respectively, the energy flux density of the soft-focused shock waves are lower than the ones of the focused shock waves. It is now possible to treat larger areas with reducing the number of shock waves necessary to cover a predefined area.

As a pulsed event, the shock wave pulses have a very broad frequency spectrum ranging from hertz to megahertz with different intensities per frequency.

After numerical integration of the square of the maximum pressure plot and multiplication with a constant factor consisting of the area and acoustic impedance within the -6dB integration limits, the total energy and energy flux density can be calculated from these pressure plots. The total energy, consisting of a positive compression part and a tensile part, is given in millijoule (mJ), the energy flux density in mJ per millimeter square (mJ/mm^2). To fully describe a shock wave, it is necessary to provide all of the above data, consisting of spatial dimension, maximum pressure, positive and tensile part of the energy, and energy flux density.

For a complete therapy description, the energy flux density, the number of pulses, pulse repetition frequency, and the number and interval of retreatments are important parameters. Unfortunately most publications lack part of the required information, which makes them difficult to compare for safety and efficacy. This might be a reason why studies investigating

the same clinical indication show divergent therapeutic results. The optimal treatment regime for many indications in orthopedics has yet to be established. Providing all necessary treatment parameters in peer-reviewed publications as stated above will be a crucial step to attaining the optimal therapeutic index for orthopedic indications. The German-speaking medical shock wave association Deutschsprachige Internationale Gesellschaft für Extrakorporale Stoßwellentherapie (DIGEST) is currently preparing the initial steps (consensus statement) for the reporting of device-specific treatment parameters and results that should be appreciated by all manufacturers and clinical users because they will gain an understanding of the best shock wave treatment parameters for each device and specific clinical indication.

Recently, nonfocused and defocused shock wave applicators have been introduced to the market. Thus far, only focused applicators were available originating from kidney stone lithotripsy where focused shock wave application was necessary to concentrate energy at one therapeutic point of interest enabling stone disintegration. Today, it is believed

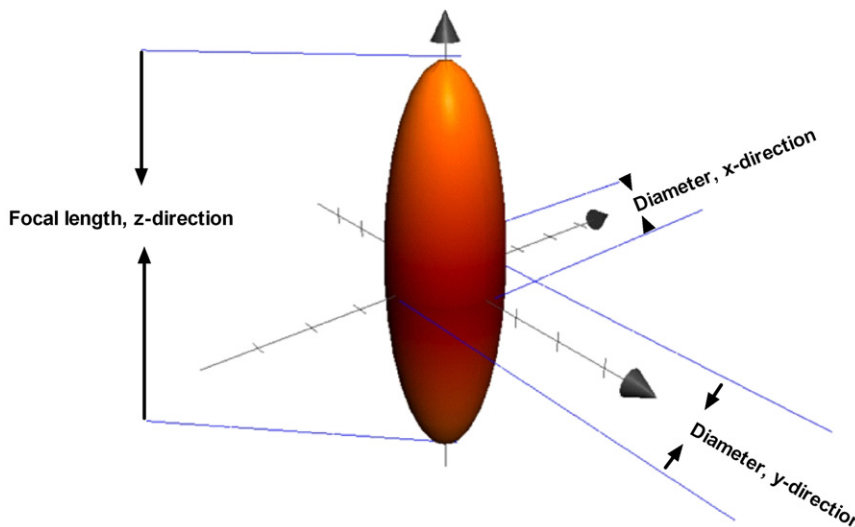
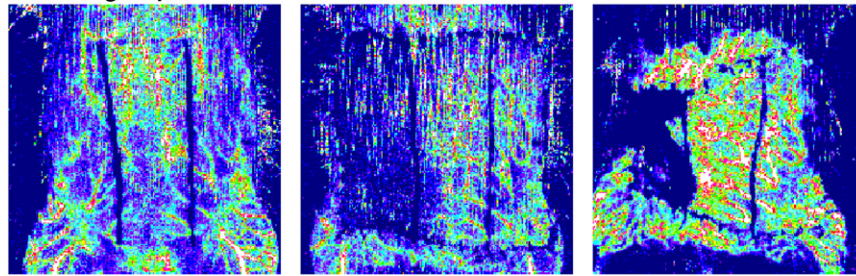


Figure 2. Spatial shape of the shock wave focal zone showing the -6dB of a typical shock wave. The absolute size varies greatly depending on the generation principle and reflector shape.

Control group

Baseline = preoperative

1 hour postischemia

7 days postischemia

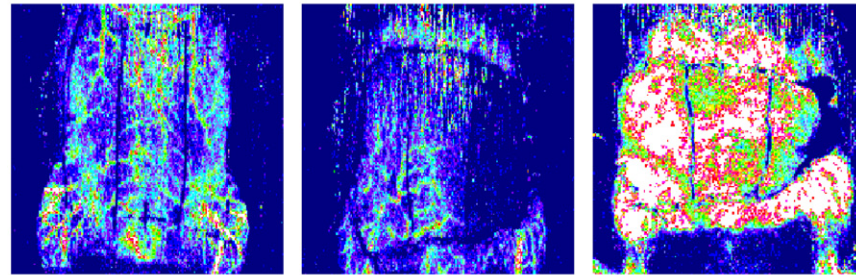
**ESWT group**

Figure 3. Superficial tissue perfusion assessed by laser Doppler imaging system in a rodent epigastric flap model. Depicted are typical perfusion images in the control group and in the ESWT group during a 7-day follow-up period. An increase in perfusion on day 7 postoperatively is evident in the flaps that were treated with shock waves. Each group had a drop in perfusion post surgery caused by ligation of the neurovascular bundle (1 hour postischemia; control group/right side; ESWT group/left side). ESWT, extracorporeal shock wave therapy.

that the working mechanisms of shock waves are based on cellular and molecular actions, which do not necessarily require focused application to the therapeutic target. Soft-focused or defocused shock wave applicators provide a larger diameter of the shock wave field and therefore cover a larger area of tissue per pulse administered. This might reduce the number of pulses and the treatment time as well as enhance patient tolerance for the treatment of superficial indications such as chronic wounds. The potential for future application, e.g., of the ischemic heart during open cardiac surgery, is now achievable due to the possibility to shape the acoustic pressure distribution according to the specific anatomic and functional requirements of new clinical indications.

POTENTIAL MECHANISM OF SHOCK WAVE THERAPY

Uncomplicated soft tissue wound healing is a complex, well-coordinated cascade of interdependent processes at both the cellular and molecular levels.^{30,39} Initial inflammation, which follows tissue injury, is beneficial for the organism because it limits continuation of tissue damage and clearance of the pathogens and sets in place cells and factors for continuation of healing cascade. Ultimately, physiological healing process leads to complete tissue repair and regeneration with near-normal restoration of tissue integrity and functionality. Wounds, particularly in the elderly, but also in patients with comorbidities such as diabetes, atherosclerosis, venous insufficiency, reduced mobility due to chronic infirmity, and hypercholesterolemia can show delayed/disturbed healing. Chronic inflammation is just one of the underlying mechanisms of delayed wound healing due to its damaging potential. Several studies have shown that a key event in the biology of wound healing is angiogenic response and in these cases of delayed wound healing, it is remarkably suppressed.^{40,41}

In compromised tissue (i.e., in the setting of hypoxia or ischemia) extracorporeal shock waves increase local tissue perfusion^{42,43} evidenced by significantly reduced laser Doppler imaging signal⁴³⁻⁴⁵ (Figure 3) in models of flap tissue necrosis following experimental iatrogenic ischemia.⁴⁶⁻⁴⁸

Nitric oxide (NO), a small ubiquitous molecule with numerous biological functions,⁴⁹ is hypothesized to play a dominant role in ESWT-mediated improvement of local blood flow in wounds, thus limiting at least in partial inflammation. In fact, NO levels were found to be elevated after treatment in vitro as well as in vivo, which correlates with the clinical findings of reduced ischemic necrosis and improved signals on laser Doppler imaging systems. Increased nonenzymatic⁵⁰ but also enzymatic (via up-regulated nitric oxide synthase (NOS) expression^{43,51,52}) production of NO are considered possible mechanisms supporting immediate post shock wave treatment improvement in ischemic tissue perfusion. NO is also important in modulating or mediating angiogenesis; thus, early NO-mediated improvement of perfusion could be complemented by new vessel in-growth (neo-vascularization) into the ischemic tissue zone. This theory is supported by the finding that wound tissue vascular endothelial growth factor, the most potent inducer of angiogenesis, is acutely increased in response to ESWT.^{42-44,53,54} Our own studies on transgenic mice⁵⁵ as well as the work of others⁵⁶ revealed an up-regulation of vascular endothelial growth factor (VEGF) receptor 2 (VEGF-R2), which is considered a primary mediator of angiogenic signaling. Furthermore, quantitative immunohistological studies evaluating ischemic tissue vessel formation showed higher vessel densities in the shock wave-treated groups.^{42,43,54,56}

An interesting clinical study by Brañes et al.⁵⁷ reported positive effects of ESWT on the angiogenesis but also evaluated effects of shock wave therapy on lymph vessel formation. The authors reported increased neo-vascularization and neo-lymphangiogenesis in patients with rotator cuff tendinopathy.

In the published literature, there are hypothesis-generating experimental data as well as clinical observations that suggest a heretofore unproven systemic effect of ESWT. Therefore, we conducted a preliminary study on uninjured transgenic (green fluorescent tagged VEGF-R2) mice.⁵⁵ In one group, a single hind limb was treated with shock waves while the contra-lateral hind limb in the same animal was left untreated (the internal control). In the untreated control group, only the basal VEGF-R2 expression in the hind limbs without shock wave treatment was measured. The VEGF-R2 levels in the treated uninjured group were higher in both the shock wave-treated limb as well as the untreated contra-lateral hind limb of the shock wave-treated animal in comparison with controls, although not statistically significant. In contrast, the control group showed baseline VEGF-R2 levels in both untreated, uninjured hind limbs.⁵⁵ Findings in the rat ischemic flap model also suggest an remote effect of ESWT, extending beyond the local shock wave-treated area (ischemic zone), as higher perfusion levels were observed not only in the ischemic zone but also in the transition zone as well as the vital zone in the shock wave-treated rats.⁵⁵ These findings led us to hypothesize a potential systemic effect of ESWT and, currently, we are in process of evaluating the systemic effects of ESWT in similar models with focus on the serum cytokine/chemokine response to the treatment.

Although the physical forces of shock waves certainly account only for a part of the observed biological efficacy, this component is very relevant in the context of angiogenesis. Endoluminal shear stress provoked by physical forces may induce drastic changes in the cytoskeleton of endothelial cells,⁵⁸ and this biomechanical force increases NOS activity,^{59,60} thereby further stimulating angiogenesis. Wang et al.⁶¹ showed in vivo Ras-dependent superoxide production following shock wave treatment, which in turn regulated cytosolic extracellular regulated kinase (ERK) phosphorylation and hypoxin-inducible factor-1 α transactivation. These intracellular changes may induce VEGF-A expression with subsequent angiogenesis. In a murine skin isograft model, Stojadinovic et al.⁵⁴ analyzed a broad spectrum of expression of angiogenesis pathway-specific genes, in mouse skin isograft model and found significantly enhanced expression in pro-angiogenic genes, ELR motif (glutamic acid–leucine–arginine sequence) positive chemokines (ELR⁺-CXC) chemokines, CC-chemokines, and cytokines.

During wound repair, platelet–cell adhesion molecule-1 (PECAM-1) on leukocytes and on endothelial cells is critically involved in the transendothelial migration processes at inflammatory sites, endothelial cell migration, and the formation of new blood vessels.⁶² Interestingly, it has been shown that PECAM-1 activation can be strongly induced by mechanical stress forces, indicating that its role in transduction of mechanical stimuli.⁶³ In response to the low energy ESWT, significant increase in PECAM-1 expression was shown histologically and confirmed with Western blot analysis for tissue protein⁶⁴ in the study of murine model of diabetes impaired wound healing and in normal healing wounds. Expression kinetics of 84 pro-angiogenic genes have shown that a single ESWT treatment turned on/augmented, for a prolonged period of time, 25–30 key pro-angiogenic genes that were previously silent in both a diabetic model and in normal healing wounds.

During regenerative processes in wounds, complex cascades of molecular as well as cellular events occur, which

interact on multiple mechanistic levels. For example, the recruitment and incorporation of progenitor cells is augmented by growth factors and chemokines such as VEGF.^{65,66} While acute ischemia shows marked overexpression of chemotactic factors, chronic ischemic tissue is characterized by reduced capability of endothelial progenitor cells (EPCs) recruitment due to limited presence of such stimulatory factors. Treatment of nonischemic and chronic ischemic tissue with extracorporeal shock waves in rats, however, induces strong expression of stromal cell-derived factor 1 (SDF-1) mRNA and is functionally linked to improved homing of previously administered EPC in nonischemic as well as in chronic ischemic tissue.⁶⁷ In addition, bone marrow-derived mononuclear cells showed a dose-dependent overexpression of VEGF mRNA and protein release following shock wave exposure in vitro.⁶⁸ Furthermore, stimulation of bone marrow-derived mononuclear cells with shock waves facilitated cell differentiation to an endothelial phenotype (VEGF⁺ and CD31⁺).⁶⁸ Similar effects were shown in an in vivo segmental bony defect rat animal model, which showed osteoblastic differentiation.⁶⁹ However, VEGF together with TGF- α 1 were also elevated in these in vitro experiments, and strong neovascularization was observed at the cartilaginous-osseous junction. ESWT-stimulated homing and differentiation of stem cells with high tissue regenerating potential, including de novo vessel formation, is promising for playing a pivotal role in clinical application.

As previously mentioned, early inflammation is beneficial for the organism; however, resolution of the inflammatory response in timely manner is key event in the physiological wound healing. Immuno-modulatory function of NO is well defined, and there is several authors suggesting that keeping the levels of NO in physiological concentrations during initial stages of wound healing is critical for successful outcome. Low energy shock wave therapy has also been shown to efficiently down-regulate necrosis factor κ b (NF- κ b) activation and NF- κ b-dependent gene expression through modification of NO levels which, in turn, regulates NF- κ b and thus diminishes pro-inflammatory stimuli.^{52,70} In vitro experiments of inflammation in cell cultures, by addition of lipopolysaccharide (LPS) and cytokines, caused rapid and significant drop in NOS activity and NO accumulation. In human umbilical vein endothelial cell and rat glioma C6 cell line after the treatment with ESWT authors reported increase in NO concentration and NOS activity and suppression of NF- κ b and NF- κ b dependent pro-inflammatory cytokines. Therefore, the observed beneficial effects of ESWT on wound healing and repair can be explained in part by its effect on NO metabolism.

In vivo studies have also shown enhanced early local inflammatory responses (high levels of macrophage-derived inflammatory protein [MIP]-1 α and MIP-1 β) in sham-treated animals when compared with ESWT-treated grafts, pointing to an anti-inflammatory mechanism of shock waves. Furthermore, shock waves significantly reduced leukocyte and macrophage infiltration into the isograft; these are pivotal cells in the inflammatory response.^{51,71} Studies have shown enhanced early local inflammatory responses (high levels of MIP-1 α and MIP-1 β) in sham-treated animals when compared with ESWT-treated grafts, pointing to an anti-inflammatory mechanism of shock waves.

Often local microbial populations either through colonization, contamination, or critical contamination maintain the

pro-inflammatory state that impairs healing in chronic wounds. The antibacterial effect of ESWT was first reported in 2000 for clinically relevant bacteria in wounds.⁷² Gerdemeyer et al.⁷³ showed that the bactericidal effect has a threshold level in terms of shock wave energy flux density and total amount of impulses and that bacterial burden in wounds was statistically reduced in a patient population receiving ESWT treatment.⁴⁵

ESWT-enhanced cell proliferation at the local wound tissue level,^{15,51,74,75} stimulated extracellular matrix metabolism,⁷⁵ decreased apoptosis,^{51,67} and down-regulated oxygen-mediated burst of leukocytes are also promising and warrant further clinical study.⁶¹

CLINICAL STUDIES

A list of indications for use of ESWT, thanks to a serendipitous finding, led to expanding shock wave therapy application from urologic and orthopedic to soft tissue indications. In the course of an ongoing prospective assessment of shock wave therapy for orthopedic nonunion and delayed union fractures in the AUVA Trauma Center Meidling, Vienna, Austria, cases complicated by osteocutaneous fistulae and/or overlying soft tissue defects (open fractures) were found to not only consolidate the disrupted bone but also heal the soft tissue wound in response to shock wave treatment, the latter with noteworthy healing velocity. Encouraged by these findings, the first human trials on wound healing were performed in August 2004 (AUVA Trauma Center Meidling) achieving very promising results. Schaden et al. in 2007 demonstrated safety and potential efficacy for low-energy defocused shock waves applied to wounds of various etiologies.⁷⁶ ESWT was performed on 208 patients (33.3% acute and 66.8% chronic wounds) in the study by Schaden et al. Within this patient population, 156 (75%) showed complete healing (100% wound epithelialization). Significant association was found between complete epithelialization and wound size (wounds <10 cm² healed in 81.0% vs. 61.8% for wounds >10 cm²) as well as between complete healing and wound duration (wounds persisting >1 month showed 57.1% healing rate vs. wounds <1 month that had a healing rate of 83%). With regard to wound etiology, venous stasis ulcers showed the lowest healing rates (36%), whereas all other wound etiologies showed at least a healing rate of 66% (arterial insufficiency ulcer—66.7%, decubital ulcer—71.4%, disturbed healing wounds—75.6%, posttraumatic tissue necrosis—86.6%, and burn wounds—100%).

In additional study, we have continued application of ESWT on patients with soft tissue indications and thus far we have included approximately 600 patients with various types of wounds whom we treated with low-energy defocused ESWT. Currently, our study is in midterm analysis (430 patients) and even though we did not finish analysis of the whole patient population, we can state that wound outcomes in association with critical wound/patient parameters found in the study by Schaden et al. did not change substantially over the course of the expanded clinical experience. In this review, for illustrative purposes, we present some of the representative images (Appendix S1) from the analyzed patient population; however, analysis of the whole patient population is ongoing and will be presented to the readership in the near future.

Peer reviewed literature evaluating ESWT for various indications is continuously accumulating. We extracted studies for soft tissue indications and focused on those that have reported findings on potential mechanism. Several published clinical studies have been performed showing efficacy of ESWT in soft tissue wound healing, particularly in chronic or/and delayed healing wounds (Table 1).

No treatment-related toxicity, infection, or deterioration of any ESWT-treated wound was evident in several studies evaluating safety and feasibility of ESWT in acute (burns⁷⁷ and skin isograft donor sites⁷⁸) and chronic (chronic ulcers⁷⁹ and diabetic [type I] foot ulcers⁸⁰) wounds.

All authors reported significantly higher rate of healing compared with control group. Elegant approach in study of ESWT effects on skin isograft donor site, somewhat overcomes differences in the wound size and depth showed higher successful rate of healing after ESWT. However, this pilot study had a small cohort of patients and needs further clinical evaluation with higher number of patients.

Larking et al.⁸¹ investigated the response of decubitus ulcerations to ESWT in a randomized, placebo-controlled crossover study. All included patients (nine ulcers) suffered from severe physical disabilities (Barthel score <8/20) with decubitus ulcerations lasting longer than 3 months in different locations. The design of the study protocol consisted of a 3-week baseline observation period in order to confirm stable wound conditions. Thereafter, ulcers were allocated to ESWT or placebo and followed-up for 4 weeks receiving treatment each week. A 2-week wash-out phase led over to treatment crossover for another 4 weeks with same treatment and evaluation parameters as in the first phase. The main finding was that ulcers that were stable over the baseline observation period showed healing after ESWT. In the group receiving the placebo regimen first (machine with typical noise but without producing shock waves), no substantial differences in wound area were recognized in the 4-week interval, but after receiving ESWT, wounds showed progressively healing. In the ESWT first group, most of the ulcers decreased in size, which was continued after crossing over in the placebo group. An interesting finding was that some of the wounds initially showed deterioration in size once the shock wave therapy started, which then turned in improvement. This phenomenon was discussed as follows that shock waves may first debride the wounds receiving proper wound bed, which is then conditioned for healing.

An interesting clinical study was performed by Wang et al.⁴⁵ comparing ESWT and HBOT for chronic diabetic foot ulcers. Seventy-two ulcers persisting longer than 3 months were assigned to one of two study groups and analyzed. In the ESWT group, 300 + 100 pulses/cm² at an energy flux density of 0.11 mJ/mm² was applied to the chronic diabetic foot ulcer every 2 weeks. The HBOT was performed using a sealed multiplace chamber at a pressure of 2.5 atmospheres absolute for 90 minutes total (25-minute sessions with 5-minute breaks). The treatment frequency was five times a week for a total of 20 treatments. Posttreatment wound care was the same in both groups. Complete ulcer healing was found in 31% of the ESWT group compared with 22% of the HBOT group, which was statistically significant. Furthermore, more than 50% improvement in terms of wound surface downsizing was observed in 89% of shock wave-treated ulcers compared with 72% of HBOT-treated ulcers, which was again statistically significant. Histological examination revealed higher cell

Table 1. Clinical studies of ESWT in soft tissue wound healing

Author	Condition(s)	Total # wounds	ESWT specifications	Shock wave generator	Complete healing (%)	Comments
Schaden et al. ⁷⁶	Disturbed healing	82	Energy flux density: 0.1 mJ/mm ²	Electrohydraulic (dermagold, TRT)	75.6	No control
	Posttraumatic necrosis	67	Amount of pulses: 100		86.6	
	Venous stasis ulcer	25	pulses/cm ²		36	
	Decubitus ulcer	14	Frequency: 5 pulses/sec		71.4	
	Plaster cast pressure ulcer	7			85.7	
	Arterial insufficiency ulcer	6			66.7	
	Burn wounds	7			100	
Ottomann et al. ⁷⁸	STSG donor sites	28	Energy flux density: 0.1 mJ/mm ²	Electrohydraulic (orthowave 180, MTS)	100	Re-epithelialization time was significantly faster in the ESWT vs. control group ($p < 0.0001$)
			Amount of pulses: 100 pulses/cm ²			
Arnó et al. ⁷⁷	Deep partial/full thickness Burn wounds	15	Energy flux density: 0.15 mJ/mm ²	Electrohydraulic (dermaPACE™, Sanuwave™)	80	No control; pilot study improvement of perfusion (LDI)
			Amount of pulses: 500			
Saggini et al. ⁷⁹	Venous ulcer	12	Energy flux density: 0.037 mJ/mm ²	Electrohydraulic (evotron, HMIT)	36	Only one (out of 10) ulcer healed in the control group (standard care treatment) ($p < 0.01$)
	Posttraumatic ulcer	16	Amount of pulses: 100 pulses/cm ²		69	
	Diabetic ulcer	4	Frequency: 4 pulses/sec		25	
Moretti et al. ⁸⁰	Diabetic plantar ulcers	32	Frequency: not specified	Electromagnetic (miniilith SL1, Storz Medical)	50	Significant faster healing and higher re-epithelialization rate compared with control group ($p < 0.001$)
			Energy flux density: 0.03 mJ/mm ²		53.33	
			Amount of pulses: 100 pulses/cm ²			
Larking et al. ⁸¹	Decubital ulcers	9	Frequency: not specified	Electrohydraulic (modified orthowave 180, MTS)	55.5	Placebo controlled crossover design showing healing in response to ESWT
			Energy flux density: 0.1 mJ/mm ²			
Wang et al. ⁴⁵	Recurrent diabetic foot ulcer	36	Amount of pulses: 200 + 100 pulses/cm ²	Electrohydraulic (orthowave 180, MTS)	31	Hyperbaric oxygen group showed complete healing in only 22% ($p < 0.001$)
			Frequency: 5 pulses/sec			
			Energy flux density: 0.11 mJ/mm ²			
			Amount of pulses: (300+) 100 pulses/cm ²			
			Frequency: not specified			

ESWT, extracorporeal shockwave therapy; mJ, milli Joule; STSG, split thickness skin grafts; LDI, laser Doppler imaging; complete healing, percentage of wounds that met healing criterion; TRT, Tissue Regenerative Technologies; MTS, Medical Technology Services.

counts and greater proliferation index in the ESWT group. Immunohistochemical staining showed significantly elevated levels of vascular endothelial growth factor and endothelial nitric oxide synthase as well as proliferation of cell nuclear antigen in the ESWT group. In addition, perfusion studies performed with laser Doppler imaging showed a significant increase in wound tissue perfusion in the ESWT group compared with the HBOT group. The authors concluded that ESWT of chronic diabetic foot ulcer is superior to HBOT, and it appears that ESWT results in increased angiogenesis and cellular events consistent with decreased cell apoptosis.

A novel approach was taken by a group from Vienna⁸² comparing the prophylactic extracorporeal shock wave treatment of areas where vein grafts were harvested for coronary artery bypass surgery with standard practice local vein harvest site procedures (=control group). They found a significantly lower ASEPSIS score in the ESWT group beginning at postoperative day 3 through day 7 as compared with the control group. Furthermore, antibiotic treatment had to be applied more often in the control group, and surgical revisions were necessary in more control group patients than in the ESWT group. The authors concluded that prophylactic ESWT could improve wound healing after vein harvesting for coronary arterial bypass surgery.

CONCLUSIONS

ESWT for the treatment of soft tissue wounds is novel approach to treat soft tissue indication. In studies currently available, it has been showed great potential and promising data for treatment of some of the difficult to heal/nonhealing wounds. Importantly, shock waves applied to wounds differ considerably from those used in lithotripsy and from those used in orthopedic applications in terms of focus, frequency of applied shockwaves, energy flux density, and total number of impulses. Shock waves used in treating problematic wounds were not determined to be destructive, rather they have been shown to induce/normalize biological responses, which stimulate and support tissue repair and regeneration. Although the mechanism of action is still under investigation, it was shown that the physical properties of shock waves are translated to complex biological responses including release of factors, cytokine, and chemokines involved in enhanced tissue perfusion and angiogenesis, both essential for the wound healing cascade. Chronic inflammation and bacterial burden also negatively affect wound healing and, therefore, the suppression of pro-inflammatory status as well as the antimicrobial effect of shock waves could further lead to improved wound healing. ESWT supporting healing of problematic wounds represents an innovative therapeutic modality, which thus far shows clinical efficacy, reproducibility, and safety. The application of shock waves to wounds is technically easy to perform, allows treatment in an outpatient setting (well tolerated without the need for analgesia), saves time, and does not require anesthetics. Due to the noninvasive nature, comparatively low costs, and the rare complications associated with this therapy, ESWT may be a valid alternative to conservative and surgical treatments in patients with chronic wound conditions. However, current clinical evidence is weak with only several studies with low patient numbers included. Therefore, it is essential to perform further randomized and controlled clinical studies with sufficient number of subjects to confirm these promising results.

ACKNOWLEDGMENTS

The views expressed in this manuscript are those of the authors and do not reflect the official policy of the Department of the Army, the Department of Defense, or the United States Government.

This effort was supported by the congressionally funded Combat Wound Initiative Program.

One of the authors is a military service member (or employee of the US Government). This work was prepared as part of official duties. Title 17 U.S.C. 105 provides the "Copyright protection under this title is not available for any work of the United States Government." Title 17 U.S.C. 101 defines a US Government work as a work prepared by a military service member or employee of the US Government as part of that person's official duties.

REFERENCES

1. Krause H. Physik und Technik Medizinischer Stoßwellensysteme. In: Rompe JD, editor. *Extrakorporale Stoßwellentherapie*. Weinheim: Chapman & Hall GmbH, 1997: 15–34.
2. Jocham D, Chaussy C, Schmiedt E. Extracorporeal shock wave lithotripsy. *Urol Int* 1986; 41: 357–68.
3. Delius M. Biological effect of shock waves—more than “just” lithotripsy? *Zentralbl Chir* 1995; 120: 259–73.
4. Coombs R, Schaden W, Zhou S. *Musculoskeletal shockwave therapy*. London: Greenwich Medical Media, 2000.
5. Thiel M. Application of shock waves in medicine. *Clin Orthop Relat Res* 2001; 387: 18–21.
6. Haupt G, Haupt A, Ekkernkamp A, Gerety B, Chvapil M. Influence of shock waves on fracture healing. *Urology* 1992; 39: 529–32.
7. Haupt G. Use of extracorporeal shock waves in the treatment of pseudarthrosis, tendinopathy and other orthopedic diseases. *J Urol* 1997; 158: 4–11.
8. Valchanou VD, Michailov P. High energy shock waves in the treatment of delayed and nonunion of fractures. *Int Orthop* 1991; 15: 181–4.
9. Vogel J, Rompe JD, Hopf C, Heine J, Burger R. High-energy extracorporeal shock-wave therapy (ESWT) in the treatment of pseudarthrosis. *Z Orthop Ihre Grenzgeb* 1997; 135: 145–9.
10. Schaden W, Fischer A, Sailler A. Extracorporeal shock wave therapy of nonunion or delayed osseous union. *Clin Orthop Relat Res* 2001; 387: 90–4.
11. Chaussy C, Eisenberger F, Jocham D. *High energy shock waves in medicine*. Stuttgart: Georg Thieme Verlag, 1997.
12. Loew M, Jurgowski W. Initial experiences with extracorporeal shockwave lithotripsy (ESWL) in treatment of tendinosis calcarea of the shoulder. *Z Orthop Ihre Grenzgeb* 1993; 131: 470–3.
13. Loew M, Jurgowski W, Thomsen M. Effect of extracorporeal shockwave therapy on tendinosis calcarea of the shoulder. A preliminary report. *Urologe A* 1995; 34: 49–53.
14. Rompe JD, Buch M, Gerdesmeyer L, Haake M, Loew M, Maier M, Heine J. Musculoskeletal shock wave therapy—current database of clinical research. *Z Orthop Ihre Grenzgeb* 2002; 140: 267–74.
15. Wang CJ. An overview of shock wave therapy in musculoskeletal disorders. *Chang Gung Med J* 2003; 26: 220–32.
16. Henney JE. From the food and drug administration. *JAMA* 2000; 284: 2178.

17. Ogden JA, Alvarez R, Levitt R, Cross GL, Marlow M. Shock wave therapy for chronic proximal plantar fasciitis. *Clin Orthop Relat Res* 2001; 387: 47–59.
18. Rompe JD. “Extracorporeal shock wave therapy for lateral epicondylitis—a double blind randomized controlled trial” by C.A. Speed *et al.* *J Orthop Res* 2002; 20: 895–8.
19. Haupt G, Chvapil M. Effect of shock waves on the healing of partial-thickness wounds in piglets. *J Surg Res* 1990; 49: 45–8.
20. Ferreira MC, Tuma P Jr, Carvalho VF, Kamamoto F. Complex wounds. *Clinics* 2006; 61: 571–8.
21. Werdin F, Tenenhaus M, Rennekampff HO. Chronic wound care. *Lancet* 2008; 372: 1860–2.
22. Schultz GS, Barillo DJ, Mazingo DW, Chin GA. Wound bed preparation and a brief history of TIME. *Int Wound J* 2004; 1: 19–32.
23. Smith RG. Enzymatic debriding agents: an evaluation of the medical literature. *Ostomy Wound Manage* 2008; 54: 16–34.
24. Ramundo J, Gray M. Enzymatic wound debridement. *J Wound Ostomy Continence Nurs* 2008; 35: 273–80.
25. Stephen-Haynes J, Thompson G. The different methods of wound debridement. *Br J Community Nurs* 2007; 12: S6, S8–14, S16.
26. Stojadinovic A, Carlson JW, Schultz GS, Davis TA, Elster EA. Topical advances in wound care. *Gynecol Oncol* 2008; 111 (Suppl. 2): S70–S80.
27. Harding KG, Morris HL, Patel GK. Science, medicine and the future: healing chronic wounds. *BMJ* 2002; 324: 160–3.
28. Brett DW. A review of moisture-control dressings in wound care. *J Wound Ostomy Continence Nurs* 2006; 33 (Suppl. 6): S3–8.
29. Okan D, Woo K, Ayello EA, Sibbald G. The role of moisture balance in wound healing. *Adv Skin Wound Care* 2007; 20: 39–53.
30. Schultz GS, Sibbald RG, Falanga V, Ayello EA, Dowsett C, Harding K, Romanelli M, Stacey MC, Teot L, Vanscheidt W. Wound bed preparation: a systematic approach to wound management. *Wound Rep Reg* 2003; 11 (Suppl. 1): S1–28.
31. Muhs BE, Gagne PJ, Maldonado T, Sheehan P. Minimally invasive revascularization strategies for chronic lower limb ischemia. *Int J Low Extrem Wounds* 2006; 5: 35–9.
32. Johnson S. Low-frequency ultrasound to manage chronic venous leg ulcers. *Br J Nurs* 2003; 12 (Suppl. 19): S14–24.
33. Al-Kurdi D, Bell-Syer SE, Flemming K. Therapeutic ultrasound for venous leg ulcers. *Cochrane Database Syst Rev* 2008; (1)CD001180.
34. Ubbink DT, Westerbos SJ, Nelson EA, Vermeulen H. A systematic review of topical negative pressure therapy for acute and chronic wounds. *Br J Surg* 2008; 95: 685–92.
35. Thackham JA, McElwain DL, Long RJ. The use of hyperbaric oxygen therapy to treat chronic wounds: a review. *Wound Rep Reg* 2008; 16: 321–30.
36. Unger HD, Lucca M. The role of hyperbaric oxygen therapy in the treatment of diabetic foot ulcers and refractory osteomyelitis. *Clin Podiatr Med Surg* 1990; 7: 483–92.
37. Cha J, Falanga V. Stem cells in cutaneous wound healing. *Clin Dermatol* 2007; 25: 73–8.
38. Eming SA, Krieg T, Davidson JM. Gene therapy and wound healing. *Clin Dermatol* 2007; 25: 79–92.
39. Falanga V. Wound healing and its impairment in the diabetic foot. *Lancet* 2005; 366: 1736–43.
40. Reed MJ, Edelberg JM. Impaired angiogenesis in the aged. *Sci Aging Knowledge Environ* 2004; 2004: e7.
41. Sadoun E, Reed MJ. Impaired angiogenesis in aging is associated with alterations in vessel density, matrix composition, inflammatory response, and growth factor expression. *J Histochem Cytochem* 2003; 51: 1119–30.
42. Oi K, Fukumoto Y, Ito K, Uwatoku T, Abe K, Hizume T, Shimokawa H. Extracorporeal shock wave therapy ameliorates hindlimb ischemia in rabbits. *Tohoku J Exp Med* 2008; 214: 151–8.
43. Yan X, Zeng B, Chai Y, Luo C, Li X. Improvement of blood flow, expression of nitric oxide, and vascular endothelial growth factor by low-energy shockwave therapy in random-pattern skin flap model. *Ann Plast Surg* 2008; 61: 646–53.
44. Kuo YR, Wang CT, Wang FS, Chiang YC, Wang CJ. Extracorporeal shock-wave therapy enhanced wound healing via increasing topical blood perfusion and tissue regeneration in a rat model of STZ-induced diabetes. *Wound Rep Reg* 2009; 17: 522–30.
45. Wang CJ, Kuo YR, Wu RW, Liu RT, Hsu CS, Wang FS, Yang KD. Extracorporeal shockwave treatment for chronic diabetic foot ulcers. *J Surg Res* 2009; 152: 96–103.
46. Meirer R, Brunner A, Deibl M, Oehlbauer M, Piza-Katzer H, Kamelger FS. Shock wave therapy reduces necrotic flap zones and induces VEGF expression in animal epigastric skin flap model. *J Reconstr Microsurg* 2007; 23: 231–6.
47. Huemer GM, Meirer R, Gurunluoglu R, Kamelger FS, Dunst KM, Wanner S, Piza-Katzer H. Comparison of the effectiveness of gene therapy with transforming growth factor-beta or extracorporeal shock wave therapy to reduce ischemic necrosis in an epigastric skin flap model in rats. *Wound Rep Reg* 2005; 13: 262–8.
48. Meirer R, Kamelger FS, Huemer GM, Wanner S, Piza-Katzer H. Extracorporeal shock wave may enhance skin flap survival in an animal model. *Br J Plast Surg* 2005; 58: 53–7.
49. Moncada S, Palmer RM, Higgs EA. Nitric oxide: physiology, pathophysiology, and pharmacology. *Pharmacol Rev* 1991; 43: 109–42.
50. Gotte G, Amelio E, Russo S, Marlinghaus E, Musci G, Suzuki H. Short-time non-enzymatic nitric oxide synthesis from L-arginine and hydrogen peroxide induced by shock waves treatment. *FEBS Lett* 2002; 520: 153–5.
51. Kuo YR, Wang CT, Wang FS, Yang KD, Chiang YC, Wang CJ. Extracorporeal shock wave treatment modulates skin fibroblast recruitment and leukocyte infiltration for enhancing extended skin-flap survival. *Wound Repair Regen* 2009; 17: 80–7.
52. Mariotto S, Cavalieri E, Amelio E, Ciampa AR, de Prati AC, Marlinghaus E, Russo S, Suzuki H. Extracorporeal shock waves: from lithotripsy to anti-inflammatory action by NO production. *Nitric Oxide* 2005; 12: 89–96.
53. Ma HZ, Zeng BF, Li XL. Upregulation of VEGF in subchondral bone of necrotic femoral heads in rabbits with use of extracorporeal shock waves. *Calcif Tissue Int* 2007; 81: 124–31.
54. Stojadinovic A, Elster EA, Anam K, Tadaki D, Amare M, Zins S, Davis TA. Angiogenic response to extracorporeal shock wave treatment in murine skin isografts. *Angiogenesis* 2008; 11: 369–80.
55. Mittermayr R, Hartinger J, Antonic V, Meinel A, Pfeifer S, Stojadinovic A, Schaden W, Redl H. Extracorporeal shock wave therapy (ESWT) minimizes ischemic tissue necrosis irrespective of application time and promotes tissue revascularization by stimulating angiogenesis. *Ann Surg* 2011; 253: 1024–32.
56. Nishida T, Shimokawa H, Oi K, Tatewaki H, Uwatoku T, Abe K, Matsumoto Y, Kajihara N, Eto M, Matsuda T, Yasui H, Takeshita A, Sunagawa K. Extracorporeal cardiac shock wave therapy markedly ameliorates ischemia-induced myocardial dysfunction in pigs in vivo. *Circulation* 2004; 110: 3055–61.

57. Brañes C, Contreras H, Cabello P, Antonic V, Guiloff L, Brañes M. Rotator cuff responses to extracorporeal shockwave therapy (ESWT): morphological and immunohistochemical analysis. *J Shoulder Elbow Surg* (In press).
58. Davies PF, Zilberberg J, Helmke BP. Spatial microstimuli in endothelial mechanosignaling. *Circ Res* 2003; 92: 359–70.
59. Corson MA, James NL, Latta SE, Nerem RM, Berk BC, Harrison DG. Phosphorylation of endothelial nitric oxide synthase in response to fluid shear stress. *Circ Res* 1996; 79: 984–91.
60. Fleming I, Bauersachs J, Fisslthaler B, Busse R. Ca²⁺-independent activation of the endothelial nitric oxide synthase in response to tyrosine phosphatase inhibitors and fluid shear stress. *Circ Res* 1998; 82: 686–95.
61. Wang FS, Wang CJ, Chen YJ, Chang PR, Huang YT, Sun YC, Huang HC, Yang YJ, Yang KD. Ras induction of superoxide activates ERK-dependent angiogenic transcription factor HIF-1 α and VEGF-A expression in shock wave-stimulated osteoblasts. *J Biol Chem* 2004; 279: 10331–7.
62. DeLisser HM, Christofidou-Solomidou M, Strieter RM, Burdick MD, Robinson CS, Wexler RS, Kerr JS, Garlanda C, Merwin JR, Madri JA, Albelda SM. Involvement of endothelial PECAM-1/CD31 in angiogenesis. *Am J Pathol* 1997; 151: 671–7.
63. Fujiwara K. Platelet endothelial cell adhesion molecule-1 and mechanotransduction in vascular endothelial cells. *J Intern Med* 2006; 259: 373–80.
64. Zins SR, Amare MF, Tadaki DK, Elster EA, Davis TA. Comparative analysis of angiogenic gene expression in normal and impaired wound healing in diabetic mice: effects of extracorporeal shock wave therapy. *Angiogenesis* 2010; 13: 293–304.
65. Grunewald M, Avraham I, Dor Y, Bachar-Lustig E, Itin A, Jung S, Chimenti S, Landsman L, Abramovitch R, Keshet E. VEGF-induced adult neovascularization: recruitment, retention, and role of accessory cells. *Cell* 2006; 124: 175–89.
66. Lee SH, Wolf PL, Escudero R, Deutsch R, Jamieson SW, Thistlethwaite PA. Early expression of angiogenesis factors in acute myocardial ischemia and infarction. *N Engl J Med* 2000; 342: 626–33.
67. Aicher A, Heeschen C, Sasaki K, Urbich C, Zeiher AM, Dimmeler S. Low-energy shock wave for enhancing recruitment of endothelial progenitor cells: a new modality to increase efficacy of cell therapy in chronic hind limb ischemia. *Circulation* 2006; 114: 2823–30.
68. Yip HK, Chang LT, Sun CK, Youssef AA, Sheu JJ, Wang CJ. Shock wave therapy applied to rat bone marrow-derived mononuclear cells enhances formation of cells stained positive for CD31 and vascular endothelial growth factor. *Circ J* 2008; 72: 150–6.
69. Chen YJ, Wurtz T, Wang CJ, Kuo YR, Yang KD, Huang HC, Wang FS. Recruitment of mesenchymal stem cells and expression of TGF- β 1 and VEGF in the early stage of shock wave-promoted bone regeneration of segmental defect in rats. *J Orthop Res* 2004; 22: 526–34.
70. Ciampa AR, de Prati AC, Amelio E, Cavalieri E, Persichini T, Colasanti M, Musci G, Marlinghaus E, Suzuki H, Mariotto S. Nitric oxide mediates anti-inflammatory action of extracorporeal shock waves. *FEBS Lett* 2005; 579: 6839–45.
71. Davis TA, Stojadinovic A, Anam K, Amare M, Naik S, Peoples GE, Tadaki D, Elster EA. Extracorporeal shock wave therapy suppresses the early proinflammatory immune response to a severe cutaneous burn injury. *Int Wound J* 2009; 6: 11–21.
72. von Eiff C, Overbeck J, Haupt G, Herrmann M, Winckler S, Richter KD, Peters G, Spiegel HU. Bactericidal effect of extracorporeal shock waves on *Staphylococcus aureus*. *J Med Microbiol* 2000; 49: 709–12.
73. Gerdesmeyer L, von Eiff C, Horn C, Henne M, Roessner M, Diehl P, Gollwitzer H. Antibacterial effects of extracorporeal shock waves. *Ultrasound Med Biol* 2005; 31: 115–9.
74. Hofmann A, Ritz U, Hessmann MH, Alini M, Rommens PM, Rompe JD. Extracorporeal shock wave-mediated changes in proliferation, differentiation, and gene expression of human osteoblasts. *J Trauma* 2008; 65: 1402–10.
75. Chao YH, Tsuang YH, Sun JS, Chen LT, Chiang YF, Wang CC, Chen MH. Effects of shock waves on tenocyte proliferation and extracellular matrix metabolism. *Ultrasound Med Biol* 2008; 34: 841–52.
76. Schaden W, Thiele R, Kolpl C, Pusch M, Nissan A, Attinger CE, Maniscalco-Theberge ME, Peoples GE, Elster EA, Stojadinovic A. Shock wave therapy for acute and chronic soft tissue wounds: a feasibility study. *J Surg Res* 2007; 143: 1–12.
77. Arno A, Garcia O, Hernan I, Sancho J, Acosta A, Barret JP. Extracorporeal shock waves, a new non-surgical method to treat severe burns. *Burns* 2010; 36: 844–9.
78. Ottomann C, Hartmann B, Tyler J, Maier H, Thiele R, Schaden W, Stojadinovic A. Prospective randomized trial of accelerated re-epithelization of skin graft donor sites using extracorporeal shock wave therapy. *J Am Coll Surg* 2010; 211: 361–7.
79. Saggini R, Figus A, Troccola A, Cocco V, Saggini A, Scuderi N. Extracorporeal shock wave therapy for management of chronic ulcers in the lower extremities. *Ultrasound Med Biol* 2008; 34: 1261–71.
80. Moretti B, Notarnicola A, Maggio G, Moretti L, Pascone M, Tafuri S, Patella V. The management of neuropathic ulcers of the foot in diabetes by shock wave therapy. *BMC Musculoskelet Disord* 2009; 10: 54.
81. Larking AM, Dupont S, Clinton M, Hardy M, Andrews K. Randomized control of extracorporeal shock wave therapy vs. placebo for chronic decubitus ulceration. *Clin Rehabil* 2010; 24: 222–9.
82. Dumfarth J, Zimpfer D, Vogeled-Kadletz M, Holfeld J, Sihorsch F, Schaden W, Czerny M, Aharinejad S, Wolner E, Grimm M. Prophylactic low-energy shock wave therapy improves wound healing after vein harvesting for coronary artery bypass graft surgery: a prospective, randomized trial. *Ann Thorac Surg* 2008; 86: 1909–13.

Supporting Information

Additional Supporting Information may be found in the online version of this article:

Appendix S1. Representative clinical cases.

Please note: Wiley-Blackwell is not responsible for the content or functionality of any supporting materials supplied by the authors. Any queries (other than missing material) should be directed to the corresponding author for the article.