

THE JOURNAL OF BONE & JOINT SURGERY

JB&JS

This is an enhanced PDF from The Journal of Bone and Joint Surgery

The PDF of the article you requested follows this cover page.

Treatment for Osteonecrosis of the Femoral Head: Comparison of Extracorporeal Shock Waves with Core Decompression and Bone-Grafting

Ching-Jen Wang, Feng-Sheng Wang, Chung-Cheng Huang, Kuender D. Yang, Lin-Hsiu Weng and Hsuan-Ying Huang

J Bone Joint Surg Am. 87:2380-2387, 2005. doi:10.2106/JBJS.E.00174

This information is current as of November 3, 2005

Reprints and Permissions

Click here to [order reprints or request permission](#) to use material from this article, or locate the article citation on jbjs.org and click on the [Reprints and Permissions] link.

Publisher Information

The Journal of Bone and Joint Surgery
20 Pickering Street, Needham, MA 02492-3157
www.jbjs.org

TREATMENT FOR OSTEONECROSIS OF THE FEMORAL HEAD: COMPARISON OF EXTRACORPOREAL SHOCK WAVES WITH CORE DECOMPRESSION AND BONE-GRAFTING

BY CHING-JEN WANG, MD, FENG-SHENG WANG, PHD, CHUNG-CHENG HUANG, MD,
KUENDER D. YANG, MD, PHD, LIN-HSIU WENG, MD, AND HSUAN-YING HUANG, MD

*Investigation performed at the Departments of Orthopaedic Surgery, Medical Research,
Diagnostic Radiology, and Pathology, Chang Gung Memorial Hospital Medical Center, Kaohsiung, Taiwan*

Background: There is continuing controversy regarding the optimal treatment for patients with symptomatic early-stage osteonecrosis of the femoral head. We compared the results of noninvasive treatment with extracorporeal shock waves with those of core decompression and bone-grafting in similar groups of patients.

Methods: Patients with stage-I, II, or III osteonecrosis were randomly assigned to be treated either with shock waves or with core decompression and nonvascularized fibular grafting. The shock-wave group consisted of twenty-three patients (twenty-nine hips), and the surgical group consisted of twenty-five patients (twenty-eight hips). The patients in the two groups had similar demographic characteristics, duration and stage of disease, and duration of follow-up. The patients in the shock-wave group received a single treatment with 6000 impulses of shock waves at 28 kV to the affected hip. The evaluation parameters included clinical assessment of pain with a visual analog pain scale, Harris hip scores, and an assessment of activities of daily living and work capacity. Radiographic assessment was performed with serial plain radiographs and magnetic resonance imaging.

Results: Before treatment, the two groups had similar pain and Harris hip scores. At an average of twenty-five months after treatment, the pain and Harris hip scores in the shock-wave group were significantly improved compared with the pretreatment scores ($p < 0.001$). In this group, 79% of the hips were improved, 10% were unchanged, and 10% were worse. Of the hips treated with a nonvascularized fibular graft, 29% were improved, 36% were unchanged, and 36% were worse. In the shock-wave group, imaging studies showed regression of five of the thirteen lesions that had been designated as stage I or II before treatment and no regression of a stage-III lesion. Two stage-II and two stage-III lesions progressed. In the surgical group, four lesions regressed and fifteen (of the nineteen graded as stage I or II) progressed. The remaining nine lesions were unchanged.

Conclusions: Extracorporeal shock-wave treatment appeared to be more effective than core decompression and nonvascularized fibular grafting in patients with early-stage osteonecrosis of the femoral head. Long-term results are needed to determine whether the effect of this novel method of treatment for osteonecrosis of the femoral head endures.

Level of Evidence: Therapeutic Level I. See Instructions to Authors for a complete description of levels of evidence.

Untreated symptomatic osteonecrosis of the femoral head usually results in collapse of the femoral head and degenerative changes of the hip joint¹⁻³. Therefore,

surgical intervention is usually indicated, with the type of procedure varying according to the severity and the radiographic stage of the disease^{4,6}. For patients with early-stage osteonecrosis of the femoral head, current joint-preserving treatment options include core decompression, vascularized or nonvascularized bone-grafting, muscle pedicle grafting, and rotational osteotomy^{3,7-9}. The results of these procedures are generally



A commentary is available with the electronic versions of this article, on our web site (www.jbjs.org) and on our quarterly CD-ROM (call our subscription department, at 781-449-9780, to order the CD-ROM).

TABLE I Patient Demographics

	Shock-Wave Group	Surgical Group
Patients/hips (no.)	23/29	25/28
Age* (yr)	39.8 ± 12.1 (19-63)	39.9 ± 9.3 (19-53)
Male/female (no. of patients)	20/3	23/2
Right/left (no. of hips)	18/11	14/14
Bilateral disease (no. of patients)	6	3
Duration of symptoms* (mo)	5.9 ± 4.5	7.1 ± 7.4
ARCO stage (no. of patients/hips)		
I	3/3	2/2
II	9/10	14/17
III	11/16	9/9
Medical history (no. of patients)		
Alcoholism	16	16
Corticosteroids	2	2
Negative	5	7
Duration of follow-up* (mo)	25.2 ± 3.7 (24-38)	25.8 ± 4.6 (24-39)

*The values are given as the mean and standard deviation with the range in parentheses.

better in patients with the earliest stages of osteonecrosis of the femoral head, and none is uniformly successful⁷⁻¹². Accordingly, the development of an effective and noninvasive treatment would be extremely valuable.

Extracorporeal shock waves have been shown to be effective in promoting bone-healing and relieving pain due to insertional tendinopathy¹³⁻¹⁸. The positive effects of shock-wave therapy on fracture-healing also have been demonstrated in animal experiments^{14,19-27}. The purpose of this study was to evaluate the effects of extracorporeal shock-wave treatment for early stages of osteonecrosis of the femoral head and to compare the results with those of core decompression and nonvascularized fibular grafting.

Materials and Methods

The institutional review board of our hospital and the Regulatory Board of the Department of Health approved this study. The inclusion criterion was stage-I, II, or III osteonecrosis of the femoral head according to the ARCO (Association Research Circulation Osseous) classification (see Appendix)⁵. The exclusion criteria included skeletal immaturity, a stage-IV lesion, immunosuppressive drug therapy, and a current or previous infection.

Between March 2001 and December 2002, forty-eight patients (fifty-seven hips) were recruited for this study. All patients signed an informed-consent form before participating in the study. The patients were randomly assigned to either the shock-wave group or the surgical group according to the day of the week of treatment. Patients who were seen on odd days of the week were assigned to the shock-wave group, and patients who were seen on even days were assigned to be treated with surgery. Twenty-three patients (twenty-nine hips) were assigned to the shock-wave group, and twenty-five pa-

tients (twenty-eight hips), to the surgical group. The patient demographics are summarized in Table I.

Pretreatment assessments consisted of a complete history and physical examination; laboratory tests, including a complete blood-cell count, a platelet count, measurement of the prothrombin time and partial thromboplastin time, chemistry profiles, and measurement of the blood urea nitrogen and creatinine levels; an electrocardiogram; a chest radiograph; and magnetic resonance imaging and radiographs of the affected hip. The diagnosis of osteonecrosis of the femoral head was confirmed with plain radiographs and/or magnetic resonance imaging.

Application of Shock Waves

Shock waves were administered with an electrohydraulic OssaTron orthotripter (High Medical Technology, Kreuzlingen, Switzerland) in one treatment, performed with the patient under general anesthesia and in the supine position. The affected hip was positioned in adduction and internal rotation with the limb secured to the table. The femoral artery was identified by digital palpation, and its location was confirmed with an ultrasound Doppler scan to avoid any direct shock-wave contact with it during the course of treatment. In patients with a stage-II or III lesion, the junctional zone between avascular and vascular bone of the femoral head was delineated under c-arm control. Four focal points, approximately 1.0 cm apart, within the junctional zone were selected, and the corresponding locations on the skin in the groin area were marked with a marker (Figs. 1-A and 1-B). In patients with a stage-I lesion, the junctional zone was selected on the basis of findings on magnetic resonance imaging. The intended depth of treatment, the center of the femoral head, was determined by raising the height of the hip on the table

until two ring markers on the machine were seen to be at that level under lateral c-arm control. Surgical lubricant was placed on each of the four skin sites prior to placement of the shock-wave tube on the skin. Each of the four points was treated with 1500 impulses of shock waves at 28 kV (equivalent to 0.62 mJ/mm² energy flux density), for a total of 6000 impulses of shock waves applied to the affected femoral head. Immediately after application of the shock waves, the groin area was inspected for ecchymosis, swelling, and hematoma. The integrity of the femoral artery was checked with the Doppler ultrasound before and after the procedure.

After treatment, patients were instructed to walk on crutches with partial weight-bearing on the affected limb for four to six weeks. Non-narcotic analgesics such as acetaminophen were prescribed for pain.

Core Decompression and Nonvascularized Fibular Grafting

Surgery was performed through a lateral approach with the patient on a fracture table and under either general or spinal anesthesia. The location of the osteonecrosis of the femoral head was verified with c-arm imaging. A guide pin was inserted from the proximal lateral femoral cortex into the femoral head. A 10-mm bone channel was made with a core reamer over the guide pin. The necrotic bone and its margins were removed with a curet, and complete removal of the necrotic lesion was verified with arthroscopic examination through the bone channel. Through a separate incision made over the anterior iliac crest on the same side, cancellous bone grafts were harvested from the anterior iliac crest, and cancellous bone chips were gently packed into the defect of the femoral head with a bone tamp. Then, a cortical fibular strut allograft was

fashioned and sized. The graft was inserted into the bone channel to maintain the cancellous bone grafts in place.

Postoperatively, the patients walked with crutches and non-weight-bearing on the affected limb for three months, then with partial weight-bearing for three months, and finally with full weight-bearing when there was radiographic evidence of graft healing.

Methods of Evaluation

Follow-up examinations were scheduled at one, three, six, and twelve months and then once a year. Clinical assessments included calculation of pain scores and Harris hip scores as well as evaluation of the ability to carry out activities of daily living and work capacity. The intensity of pain was recorded on a visual analog scale ranging from 0 to 10, with 0 indicating no pain and 10 indicating severe pain. The Harris hip score measures pain, function, activity, and motion of the hip¹⁰. The evaluation of activities of daily living included determination of the level of activity; walking capacity with or without support; the length of time that the patient could walk; and the ability to ascend and descend stairs, change from a sitting to a standing position, and put on shoes and socks. The work capacity in the previous three months included the number of days absent from work or school. The clinical outcome was defined as "improved" if the patient had a $\geq 50\%$ reduction in hip pain and a $\geq 50\%$ improvement in hip function in activities of daily living, "unchanged" if the patient had a $< 50\%$ reduction in hip pain and a $< 50\%$ improvement in hip function in activities of daily living, and "worse" if the patient had more hip pain and less hip function compared with the pre-treatment status.

Anteroposterior and lateral radiographs were made be-

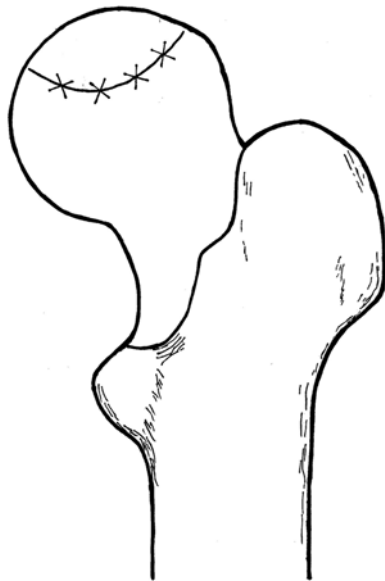


Fig. 1-A

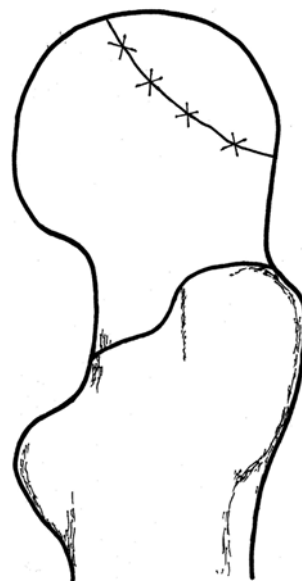


Fig. 1-B

Sketches of anteroposterior (Fig. 1-A) and lateral (Fig. 1-B) views of the hip, showing the junctional zone between the avascular and vascular bones of the femoral head and the four overlying skin markers (X's) for shock-wave application.

TABLE II Pain Scores in Shock-Wave and Surgical Groups Before and After Treatment

	Before Treatment	6 Mo	12 Mo	24 Mo
Shock-wave group				
No. of patients	23	22	22	20
No. of hips	29	28	28	26
Pain score* (points)	4.3 ± 2.8 (2-9)	1.4 ± 1.6 (0-5)	0.8 ± 1.2 (0-5)	0.4 ± 0.6 (0-2)
Difference compared with pretreatment score (p value)		<0.001	<0.001	<0.001
Surgical group				
No. of patients	25	25	21	18
No. of hips	28	28	22	19
Pain score* (points)	5.1 ± 1.0 (4-9)	5.0 ± 1.4 (3-7)	4.9 ± 1.4 (3-7)	4.7 ± 1.6 (3-7)
Difference compared with pretreatment score (p value)		0.735	0.658	0.539
Difference compared with shock-wave group (p value)	0.071	<0.001	<0.001	<0.001

*The values are given as the mean and standard deviation with the range in parentheses. The pain score was measured on a visual analog scale ranging from 0 to 10, with 0 indicating no pain and 10 indicating severe pain.

fore treatment; at three, six, and twelve months after treatment; and then once a year. Plain radiographs of the hip were used to evaluate the size of the lesion, the extent of collapse of subchondral bone, and degenerative changes of the hip joint. Magnetic resonance imaging (Horizon, 1.5-T; GE Medical Systems, Milwaukee, Wisconsin) was performed before treatment, at six and twelve months after treatment, and then once a year with axial, coronal, and sagittal T1-weighted images; coronal proton-weighted and T2-weighted images; and sagittal fast-spin-echo T2-weighted fat-suppression images. These images were utilized to examine the size of the lesion, the congruency of the femoral head, the presence of a crescent sign, bone marrow edema, and degenerative changes of the hip joint. A radiologist who was blinded to the nature of the treatment evaluated the findings on the radiographs and magnetic resonance images.

Statistical Analysis

The Student t test was used to compare the pretreatment and posttreatment values in each group, and the Mann-Whitney U test was used to compare the shock-wave group and the surgical group. Significance was set at $p < 0.05$. The primary outcome end point was conversion to a total hip arthroplasty. The secondary end point was a decrease in hip pain and an improvement in hip function.

Results

The pain scores for both groups are summarized in Table II. The pretreatment pain scores of the two groups did not differ significantly from each other. In the shock-wave group, the mean pain score significantly improved at each time interval ($p < 0.001$), whereas, with the numbers available, it did not significantly improve at the consecutive time intervals in the

TABLE III Harris Hip Scores in Shock-Wave and Surgical Groups Before and After Treatment

	Before Treatment	6 Mo	12 Mo	24 Mo
Shock-wave group				
No. of patients	23	22	22	20
No. of hips	29	28	28	26
Harris hip score*	78.7 ± 13.5 (57-98)	92.1 ± 8.4 (67-100)	93.5 ± 8.5 (57-100)	97.5 ± 2.9 (93-100)
Difference compared with pretreatment score (p value)		<0.001	<0.001	<0.001
Surgical group				
No. of patients	25	25	21	18
No. of hips	28	28	22	19
Harris hip score*	74.6 ± 4.7 (62-88)	74.9 ± 5.3 (65-89)	75.0 ± 5.4 (68-89)	76.8 ± 5.6 (68-89)
Difference compared with pretreatment score (p value)		0.406	0.774	0.116
Difference compared with shock-wave group (p value)	0.066	<0.001	<0.001	<0.001

*The values are given as the mean and standard deviation with the range in parentheses.

TABLE IV Overall Clinical Outcomes in Shock-Wave and Surgical Groups

	Total Series		Stage-I Lesions		Stage-II Lesions		Stage-III Lesions	
	Shock-Wave Group	Surgical Group	Shock-Wave Group	Surgical Group	Shock-Wave Group	Surgical Group	Shock-Wave Group	Surgical Group
Total no. of hips	29	28	3	2	10	18	16	8
Improved	23	8	3	1	8	6	12	1
Unchanged	3	10	0	1	1	7	2	2
Worse	3	10	0	0	1	5	2	5
Total hip arthroplasty*	3	9	0	0	1	4	2	5
Difference between treatment groups (<i>p value</i>)	<0.001							

*Of the three total hip arthroplasties (performed in three patients) in the shock-wave group, two were done because of disease progression at four and thirteen months after the shock-wave treatment and one was done because of hip infection. Of the nine total hip arthroplasties (performed in seven patients) in the surgical group, six were done at one year and three were done at two to three years after the index surgery.

surgical group. At each time interval, the mean pain score was significantly better in the shock-wave group than in the surgical group ($p < 0.001$).

The Harris hip scores of the shock-wave and surgical groups are summarized in Table III. Before treatment, the groups had comparable hip scores ($p = 0.066$). After treatment, significant improvement in the mean Harris hip score was noted at each time interval in the shock-wave group ($p < 0.001$), but the serial changes in the surgical group were not significant. The shock-wave group was found to have a significantly better mean hip score than the surgical group at each time interval ($p < 0.001$).

The clinical outcomes in the shock-wave and surgical

groups are summarized in Table IV. In the shock-wave group, the overall result was improved in 79% (twenty-three) of the twenty-nine hips, it was unchanged in 10% (three), and it was worse in 10%. In the surgical group, the result was improved in 29% (eight) of the twenty-eight hips, it was unchanged in 36% (ten), and it was worse in 36%. The majority of the patients in the shock-wave group reported substantial relief of night pain and less restricted hip motion after treatment. Total hip arthroplasty was performed in three patients (three hips; 10%) in the shock-wave group and in seven patients (nine hips; 32%) in the surgical group. In the shock-wave group, total hip arthroplasty was performed because of progression of the lesion in two hips, at four and thirteen months after treat-

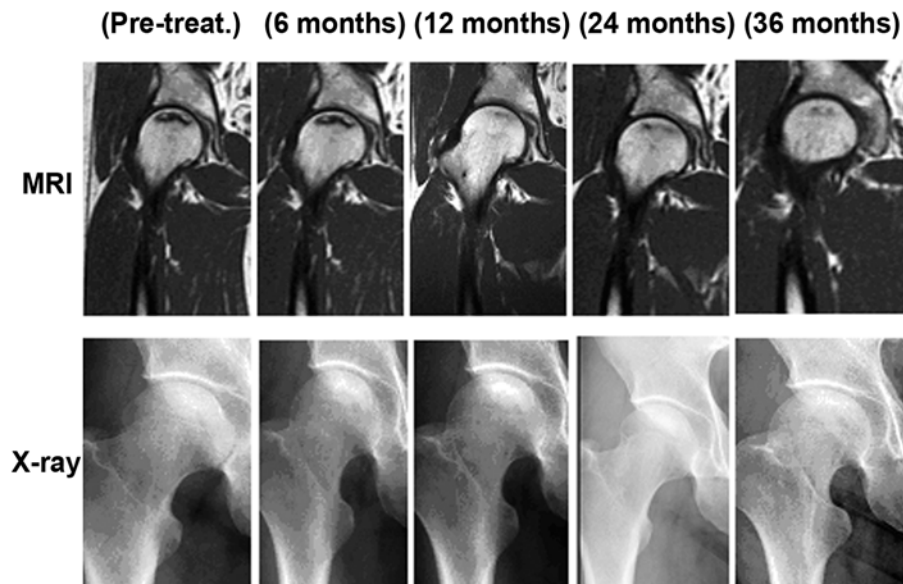


Fig. 2

Serial T1-weighted magnetic resonance images (MRI) and radiographs (X-ray) of the right hip of a forty-year-old man, made before shock-wave treatment for stage-II osteonecrosis of the femoral head and at six, twelve, twenty-four, and thirty-six months after treatment. The lesion regressed, and the patient had no pain in the right hip, which was fully functional, thirty-six months after the shock-wave treatment.

TABLE V Sizes of the Lesions on Radiographs and Magnetic Resonance Images Before and After Treatment

	Before Treatment	6 Mo	12 Mo	24 Mo
Shock-wave group				
No. of patients	23	22	22	20
No. of hips	29	28	28	26
Size of lesion* (%)	61 ± 41 (1-73)	29 ± 19 (1-65)	30 ± 20 (1-67)	30 ± 20 (1-65)
Difference compared with pretreatment score (<i>p</i> value)		0.282	0.258	0.369
Surgical group				
No. of patients	25	25	21	19
No. of hips	28	28	22	20
Size of lesion* (%)	40 ± 23 (11-87)	46 ± 4 (40-52)	42 ± 15 (42-52)	41 ± 27 (45-64)
Difference compared with pretreatment score (<i>p</i> value)		0.126	0.357	0.169
Difference compared with shock-wave group (<i>p</i> value)	0.092	<0.001	0.003	0.040

*The values, given as the mean and standard deviation with the range in parentheses, represent the percentage of the involved area of the femoral head.

ment, and because of infection of the hip secondary to pneumonia and septicemia in another hip. In the surgical group, total hip arthroplasty was performed because of progression of the lesion, at one year after the index surgery in four patients (six hips) and at two to three years in three patients (three hips).

In the shock-wave group, thirteen patients had had a prior total hip arthroplasty on the contralateral hip. Of those patients, six stated that they had less thigh pain and better hip function on the side that had been treated with the shock-wave therapy than on the side treated with the arthroplasty, three patients preferred the side treated with the total hip arthroplasty, and four patients reported comparable function of the two hips.

The changes in the sizes of the lesions as seen on the radiographs and the magnetic resonance images made after treatment are summarized in Table V. In the shock-wave group, there was a trend toward a decrease in the size of the lesion, compared with the pretreatment size, at each time interval, but the magnitudes of the changes were not significant. In

the surgical group, there was no significant serial regression of the lesions. When compared with the surgical group, the shock-wave group had a significantly greater mean decrease in the size of the lesion at each time interval ($p < 0.001$, 0.003 , and 0.040).

The radiographic stages of the lesions before and after treatment are summarized in Table VI. In the shock-wave group, there was regression of five of the thirteen lesions that had been graded as stage I or II (Fig. 2), whereas none of the stage-III lesions regressed. Four lesions, two of which were stage II and two of which were stage III, progressed. The remaining lesions were seen to be unchanged on the radiographs and magnetic resonance images. In the surgical group, four lesions regressed and fifteen of the nineteen lesions that had been stage I or II progressed. The remaining nine lesions in that group were unchanged. There were minimal changes in the stage-III lesions, as seen on plain radiographs and magnetic resonance imaging, in both groups despite the clinical improvement in the patients who had undergone shock-wave treatment. With the number of hips available, we did not find

TABLE VI Changes in the Stages of the Lesions as Seen on Radiographs and Magnetic Resonance Images Before and After Treatment*

	Total Series		Stage-I Lesions		Stage-II Lesions		Stage-III Lesions	
	Shock-Wave Group	Surgical Group	Shock-Wave Group	Surgical Group	Shock-Wave Group	Surgical Group	Shock-Wave Group	Surgical Group
Before treatment†	29	28	3	2	10	18	16	8
After treatment†	29	28	5	1	6	3	18	24

*In the shock-wave group, five lesions (three stage I and two stage II) regressed and four (two stage II and two stage III) progressed. In the surgical group, four lesions regressed, fifteen (fourteen stage II and one stage I) progressed, and nine were unchanged. †The values are given as the number of lesions.

a difference in outcome according to the etiology of the osteonecrosis of the femoral head.

Complications

There were no neuromuscular, systemic, or device-related problems in the shock-wave group. Local complications included ecchymosis and mild swelling of the groin area in fourteen hips (48%); these problems spontaneously resolved after ice packs had been used for a few days. In the surgical group, there were no infections, perforations of the articular cartilage of the femoral head, or graft migration. Pain at the iliac crest donor site was reported by sixteen patients (58%); all but one had improvement over the next four to twelve months.

Discussion


Many surgical procedures have been proposed for the treatment of early stages of osteonecrosis of the femoral head^{4,6-9}. Core decompression with or without bone-grafting is a commonly employed procedure, but many studies have demonstrated poor outcomes of femoral head-preserving procedures, including core decompression⁷⁻⁹. In the current study, we found that treatment with a noninvasive technique resulted in regression of five of thirteen lesions that had been designated as stage I or II before treatment, progression of only four (15%) of twenty-six lesions that had been stage II or III, and no regression of any stage-III lesion. It appeared, therefore, that shock-wave therapy altered the natural course of early osteonecrosis of the femoral head, as seen at an average of twenty-five months after treatment. The results of the current study were comparable with or better than those reported in other series^{13,28}. At the time of final follow-up, fewer patients had undergone total hip arthroplasty in the shock-wave group than in the group treated with nonvascularized fibular grafting ($p < 0.001$). Additionally, the pain scores and Harris hip scores were significantly better in the shock-wave group than in the surgical group ($p < 0.001$).

The mechanism by which shock-wave treatment results in clinical improvement remains unknown. It has been postulated that shock waves induce hyperstimulation analgesia by increasing the threshold of pain and promote bone-healing as a result of microfracture^{15,17}. Recently, animal experiments demonstrated that shock-wave treatment stimulated neovascularization in association with an increased expression of angiogenic growth markers including endothelial nitric oxide synthase (eNOS), vessel endothelial growth factor (VEGF),

and proliferating cell nuclear antigen (PCNA) in tendon and bone and at tendon-bone interfaces^{29,30}. We speculated that shock-wave treatment may provide an analgesic effect by increasing the pain threshold and may alter the pathophysiology of the condition by altering the vascularity of the affected parts of the femoral head.

In summary, extracorporeal shock-wave treatment appeared to be more effective than core decompression and nonvascularized fibular grafting for providing short-term pain relief for patients affected by early stages of osteonecrosis of the femoral head. We surmised, on the basis of radiographic and magnetic resonance imaging findings, that there may have been advantageous biologic effects as well. Long-term results are needed to confirm the efficacy of this novel treatment for osteonecrosis of the femoral head.

Appendix

 A table showing the ARCO (Association Research Circulation Osseous) classification system is available with the electronic versions of this article, on our web site at jbjs.org (go to the article citation and click on "Supplementary Material") and on our quarterly CD-ROM (call our subscription department, at 781-449-9780, to order the CD-ROM). ■

Ching-Jen Wang, MD
Feng-Sheng Wang, PhD
Chung-Cheng Huang, MD
Kuender D. Yang, MD, PhD
Lin-Hsiu Weng, MD
Hsuan-Ying Huang, MD

Departments of Orthopaedic Surgery (C.-J.W. and L.-H.W.), Medical Research (F.-S.W. and K.D.Y.), Diagnostic Radiology (C.-C.H.), and Pathology (H.-Y.H.), Chang Gung Memorial Hospital Medical Center, 123 Ta-Pei Road, Niao-Sung Hsiang, Kaohsiung 833, Taiwan. E-mail address for C.-J. Wang: w281211@adm.cgmh.org.tw

In support of their research or preparation of this manuscript, one or more of the authors received grants or outside funding from the Chang Gung Research Fund (CMRP 8010), National Science Council (NSC 92-2314-B-182A-100), and National Health Research Institute (NHRI-EX94-9423EP). None of the authors received payments or other benefits or a commitment or agreement to provide such benefits from a commercial entity. No commercial entity paid or directed, or agreed to pay or direct, any benefits to any research fund, foundation, educational institution, or other charitable or nonprofit organization with which the authors are affiliated or associated.

doi:10.2106/JBJS.E.00174

References

- Merle d'Aubigné R, Postel M, Mazabraub A, Massias P, Gueguen J, France P. Idiopathic necrosis of the femoral head in adults. *J Bone Joint Surg Br.* 1965; 47:612-33.
- Ohzono K, Saito M, Takaoka K, Ono K, Saito S, Nishina T, Kadowaki T. Natural history of nontraumatic avascular necrosis of the femoral head. *J Bone Joint Surg Br.* 1991;73:68-72.
- Takatori Y, Kokubo T, Ninomiya S, Nakamura S, Morimoto S, Kusaba I. Avascular necrosis of the femoral head. Natural history and magnetic resonance imaging. *J Bone Joint Surg Br.* 1993;75:217-21.
- Ficat RP. Idiopathic bone necrosis of the femoral head. Early diagnosis and treatment. *J Bone Joint Surg Br.* 1985;67:3-9.
- Gardeniers JWM. ARCO report of the Committee of Staging and Nomenclature. *ARCO News Letter.* 1993;5:79-82.
- Steinberg ME, Hayken GD, Steinberg DR. A quantitative system for staging avascular necrosis. *J Bone Joint Surg Br.* 1995;77:34-41.
- Koo KH, Kim R, Ko GH, Song HR, Jeong ST, Cho SH. Preventing collapse in early osteonecrosis of the femoral head. A randomised clinical trial of core decompression. *J Bone Joint Surg Br.* 1995;77:870-4.

- 8.** Learmonth ID, Maloon S, Dall G. Core decompression for early atraumatic osteonecrosis of the femoral head. *J Bone Joint Surg Br.* 1990;72:387-90.
- 9.** Saito S, Ohzono K, Ono K. Joint-preserving operations for idiopathic avascular necrosis of the femoral head. Results of core decompression, grafting and osteotomy. *J Bone Joint Surg Br.* 1988;70:78-84.
- 10.** Harris WH. Traumatic arthritis of the hip after dislocation and acetabular fractures: treatment by mold arthroplasty. An end-result study using a new method of result evaluation. *J Bone Joint Surg Am.* 1969;51:737-55.
- 11.** Wei SY, Klimkiewicz JJ, Lai M, Garino JP, Steinberg ME. Revision total hip arthroplasty in patients with avascular necrosis. *Orthopedics.* 1999;22:747-57.
- 12.** D'Antonio JA, Capello WN, Manley MT, Feinberg J. Hydroxyapatite coated implants. Total hip arthroplasty in the young patient and patients with avascular necrosis. *Clin Orthop Relat Res.* 1997;344:124-38.
- 13.** Burger RA, Witzsch U, Haist J, Karnosky V, Hohenfellner R. Extracorporeal shockwave therapy of pseudo-arthritis and aseptic osteonecrosis. *J Endourol.* 1991;5:S48.
- 14.** McCormack D, Lane H, McElwain J. The osteogenic potential of extracorporeal shock wave therapy. An in-vivo study. *Ir J Med Sci.* 1996;165:20-2.
- 15.** Ogden JA, Tóth-Kischkat A, Schultheiss R. Principles of shock wave therapy. *Clin Orthop Relat Res.* 2001;387:8-17.
- 16.** Rompe JD, Rosendahl T, Schöllner C, Theis C. High-energy extracorporeal shock wave treatment of nonunions. *Clin Orthop Relat Res.* 2001;387:102-11.
- 17.** Schaden W, Fischer A, Sailler A. Extracorporeal shock wave therapy of nonunion or delayed osseous union. *Clin Orthop Relat Res.* 2001;387:90-4.
- 18.** Wang CJ, Chen HS, Chen CE, Yang KD. Treatment of nonunions of long bone fractures with shock waves. *Clin Orthop Relat Res.* 2001;387:95-101.
- 19.** Chen YJ, Wurtz T, Wang CJ, Kuo YR, Yang KD, Huang HC, Wang FS. Recruitment of mesenchymal stem cells and expression of TGF-beta 1 and VEGF in the early stage of shock wave-promoted bone regeneration of segmental defect in rats. *J Orthop Res.* 2004;22:526-34.
- 20.** Delius M, Draenert K, Al Diek Y, Draenert Y. Biological effects of shock waves: in vivo effect of high energy pulses on rabbit bone. *Ultrasound Med Biol.* 1995;21:1219-25.
- 21.** Johannes EJ, Kaulesar Sukul DM, Matura E. High-energy shock waves for the treatment of nonunions: an experiment on dogs. *J Surg Res.* 1994;57:246-52.
- 22.** Kaulesar Sukul DM, Johannes EJ, Pierik EG, van Eijck GJ, Kristelijin MJ. The effect of high energy shock waves focused on cortical bone: an in vitro study. *J Surg Res.* 1993;54:46-51.
- 23.** Wang CJ, Huang HY, Chen HH, Pai CH, Yang KD. Effect of shock wave therapy on acute fractures of the tibia: a study in a dog model. *Clin Orthop Relat Res.* 2001;387:112-8.
- 24.** Wang FS, Wang CJ, Huang HJ, Chung H, Chen RF, Yang KD. Physical shock wave mediates membrane hyperpolarization and Ras activation for osteogenesis in human bone marrow stromal cells. *Biochem Biophys Res Commun.* 2001;287:648-55.
- 25.** Wang FS, Yang KD, Kuo YR, Wang CJ, Sheen-Chen SM, Huang HC, Chen YJ. Temporal and spatial expression of bone morphogenetic proteins in extracorporeal shock wave-promoted healing of segmental defect. *Bone.* 2003;32:387-96.
- 26.** Wang FS, Yang KD, Chen RF, Wang CJ, Sheen-Chen SM. Extracorporeal shock wave promotes growth and differentiation of bone marrow stromal cells towards osteoprogenitors associated with TGF-beta1. *J Bone Joint Surg Br.* 2002;84:457-61.
- 27.** Yang C, Heston WD, Gulati S, Fair WR. The effects of high energy shock waves (HESW) on human bone marrow. *Urol Res.* 1988;16:427-9.
- 28.** Ludwig J, Lauber S, Lauber HJ, Dreisilker U, Raedel R, Hotzinger H. High-energy shock wave treatment of femoral head necrosis in adults. *Clin Orthop Relat Res.* 2001;387:119-26.
- 29.** Wang CJ, Huang HY, Pai CH. Shock wave-enhanced neovascularization at the tendon-bone junction: an experiment in dogs. *J Foot Ankle Surg.* 2002;41:16-22.
- 30.** Wang CJ, Wang FS, Yang KD, Weng LH, Hsu CC, Huang CS, Yang LC. Shock wave therapy. *Orthop Res.* 2003;21:984-9.