

Extracorporeal Shock Wave Therapy for Resistant Stress Fracture in Athletes

A Report of 5 Cases

Masanori Taki,^{*†} MD, Osamu Iwata,[‡] MD, Masaki Shiono,[‡] MD, PhD,
Masashi Kimura,[†] MD, PhD, and Kenji Takagishi,[§] MD, PhD

From the [†]Zensyukai Hospital Gunma Sports Medicine Research Center, Gunma, Japan, the [‡]Department of Orthopaedic Surgery, Shonan Kamakura General Hospital, Kanagawa, Japan, and the [§]Department of Orthopaedic Surgery, Gunma University Graduate School of Medicine, Gunma, Japan

Keywords: extracorporeal shock wave therapy (ESWT); stress fracture; delayed union; nonunion

A stress fracture is a major problem for athletes. It is sometimes difficult to repair, resulting in delayed union or nonunion. For intractable cases, we often perform surgical treatment using some internal fixation device with or without bone grafting. Hulkko and Orava¹² reported 368 stress fractures of which 26 fractures (7.1%) required surgical treatment because of dislocation or delayed union/nonunion. However, surgical treatment can sometimes lead to complications.^{3,5,15,26}

Consequently, there is interest in developing an effective nonsurgical technique for treating stress fracture.^{1,2,22} Recently, extracorporeal shock wave therapy (ESWT) has been reported as an effective noninvasive technique for fracture healing^{6,10,14} and delayed union/nonunion.¹³

We performed ESWT for resistant stress fractures that were not healed conservatively or operatively, and we report efficacy and short-term results. The purpose of this study was to evaluate the effects of ESWT for stress fracture, especially in resistant cases.

MATERIALS AND METHODS

From 1997 to 2003, 62 patients underwent ESWT for delayed union or nonunion at our hospital, including 5 athletes with chronic stress fracture. The 5 patients were 4 men

and 1 woman, ranging in age from 17 to 22 years (mean, 19.0 years). They participated in the following sports: baseball (2), basketball (1), soccer (1), and marathon (1). The diagnoses were the following stress fractures: middle third tibia (2), base of the fifth metatarsal bone (1), inferior pubic ramus (1), and medial malleolus of the ankle (1). The time interval between the initial symptoms and ESWT ranged from 6 to 25 months (mean, 12 months). All patients were treated conservatively (and 2 patients surgically) before ESWT for 6 to 12 months (mean, 7.6 months), but they did not heal.

Extracorporeal shock wave therapy was performed only once under spinal anesthesia in an operating room. The shock waves were generated by OssaTron (High Medical Technologies, Lengwil, Switzerland), which is an electrohydraulic shockwave device. The fracture site was identified by a C-arm image intensifier. After fracture position and depth had been determined, surgical lubrication gel was applied topically over the skin region, which was then put in direct contact with the OssaTron tube. The shock wave intensity was 22 to 28 kV (at 0.29-0.4 mJ/mm²), and the number of shocks was 2000 to 4000. They were estimated based on technical instructions provided by the manufacture of OssaTron (Table 1). After this treatment, 2 stress fractures, which were unstable pseudarthroses, were fixed with casts for 4 weeks, because when the fracture is unstable, adequate immobilization after ESWT is important for fracture healing.^{23,25} The other three patients with stress fractures were ordered to stop sports activities.

Follow-up was performed in our outpatient clinic. Bony consolidation was confirmed radiographically. When necessary, CT was used to further support this analysis. After bone union was achieved, a return to sports was permitted only when the patient was able to participate without

*Address correspondence to Masanori Taki, MD, Zensyukai Hospital Gunma Sports Medicine Research Center, 1381 Ninomiya-machi Maebashi, Gunma, Japan 379-2117 (e-mail: taki@zensyukai.com).

No potential conflict of interest declared.

TABLE 1
Guideline for Shock Wave Intensity^a

Area	Times	Dose, kV
Humerus	3000	28
Ulna	2000	24
Hand and foot	1500	20
Femur and tibia	4000	28

^aData from High Medical Technologies Inc, Switzerland.

restrictions caused by pain. The average follow-up period was 2 years (range, 12 months to 3 years).

CASE REPORTS

Case 1

A 22-year-old male basketball player visited our clinic 8 months after the initial midanterior leg pain developed. He had already stopped sports activities for 6 months because of stress fracture of the middle third tibia diagnosed at another clinic, but radiographic improvement was not observed. His midanterior leg had swelling and tenderness. Radiographs showed midanterior cortical radiolucency. We diagnosed resistant chronic stress fracture of the middle third tibia and performed ESWT. The doses of shock waves were 4000 impulses at 28 kV. After ESWT, we ordered the athlete to continue to refrain from sports activities, especially running and jumping. Radiographic improvement was observed at 1.5 months, and he has expressed no pain and no tenderness since then. At 3.5 months, radiographic consolidation was achieved, after which he started jogging. At 4.5 months, he returned to basketball completely. At 1.5 years after ESWT, the bony union was fully developed in the radiographs, and he played basketball without difficulty (Table 2, Figure 1).

Case 2

This case is a 13-year-old male baseball player: After the initial symptoms (midanterior leg pain when jumping and running) developed, he had stopped running and jumping more than 6 months for stress fracture of the middle third tibia. However, his midanterior leg still had tenderness. Radiographs showed radiolucency through the thickened

cortex of the midanterior tibia and tibial growth plates. We diagnosed recalcitrant chronic stress fracture of the middle third tibia and performed ESWT. The doses of shock waves were 3000 impulses at 28 kV. After ESWT, we ordered the player to continue to refrain from sports activities, especially running and jumping. At 1 month after ESWT, radiographic improvement was observed and he has expressed no pain since then. At 3 months, radiographic consolidation was achieved, after which he started jogging. At 4 months, he returned to baseball. He played baseball without recurrence for 3 years after ESWT (Figure 2).

Case 3

A 22-year-old female elite marathon runner was seen with groin pain and was diagnosed with a stress fracture of the inferior pubic ramus at another hospital. After the diagnosis, the patient did almost no running. But when she did run once over a span of a few months, the groin pain soon returned. At 1 year after the initial diagnosis, her symptoms and radiographic fracture persisted. At that point we decided to perform ESWT. The doses of shock waves were 2000 impulses at 24 kV. After ESWT, we ordered her to continue to refrain from running. At 1 month after ESWT, bony consolidation was observed on radiography. At 3 months, fusion was complete, and she expressed no pain and no tenderness. Subsequently, she resumed running. At 1 year after ESWT, her performance recovered enough for her to win a road race. The bony union was more complete in the radiographs (Figure 3).

Case 4

A 21-year-old male soccer player was seen with a stress fracture of the fifth metatarsal base. Although he had no acute injury, his initial symptom was lateral side foot pain when he was running and stopping while playing soccer. One month later he was diagnosed with a stress fracture of the fifth metatarsal base. He had stopped sports activities for 3 months, but radiographic improvement was not observed. Then he underwent internal fixation with bone graft. After surgery he used a 3-week nonweightbearing short leg cast and a 2-week weightbearing short leg cast. Because of the persistence of the fracture site at 2 months after surgery, an additional 5 weeks in the weightbearing short leg cast was used. However, bony union was still not achieved. We performed ESWT at 4 months after surgery.

TABLE 2
Clinical Data and Results After Extracorporeal Shock Wave Therapy (ESWT)

Case	Age, Years/ Sex	Sport	Surgical History	Initial Pain to ESWT, Months	Initial Treatment to ESWT, Months	Bony Union After ESWT, Months	Return to Sport, Months
1	22/M	Basketball	—	8	6	3.5	4.5
2	13/M	Baseball	—	6	6	3	3.5
3	22/F	Marathon	—	13	12	3	3
4	21/M	Soccer	IF+BG ^a	8	7	2	3
5	17/M	Baseball	IF+BG	25	7	3	6

^aIF+BG, internal fixation with bone graft.

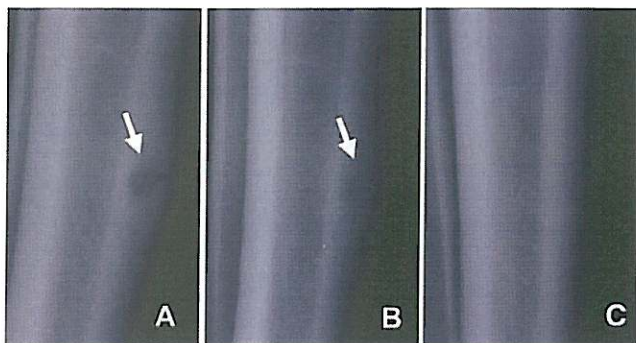


Figure 1. Case 1 (22-year-old male basketball player). A, stress fracture of middle third tibia before extracorporeal shock wave therapy (ESWT); B, at 3.5 months after ESWT, consolidation is seen; C, at 1.5 years after ESWT, consolidation is fully developed.

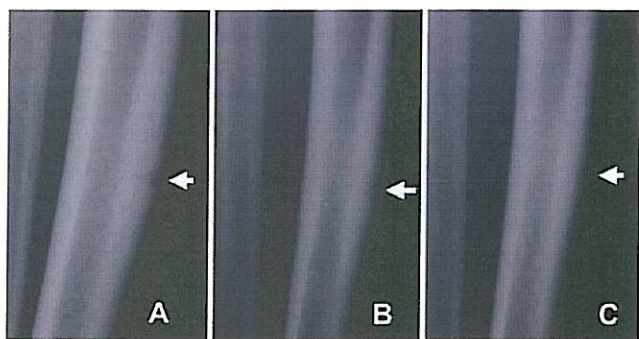


Figure 2. Case 2 (13-year-old male baseball player). A, stress fracture of middle third tibia before extracorporeal shock wave therapy (ESWT); B, at 1 month after ESWT, consolidation is seen; C, at 3 months after ESWT, consolidation is achieved.

The doses of shock waves were 2000 impulses at 20 kV. After ESWT, we used a nonweightbearing short leg cast for 4 weeks. At 1 month, bony consolidation appeared on radiography. At 2 months, fusion became complete. Then he started running, and he was able to return to soccer 3 months after ESWT. At 1 year after ESWT, the bony union was intact and fully developed in the radiographs (Figure 4).

Case 5

A 17-year-old male baseball player was seen with medial left ankle pain for 17 months before initial diagnosis. When he was given a diagnosis of a stress fracture of the medial malleolus of the left ankle, it had already developed chronic nonunion of the stress fracture. He underwent internal fixation with bone graft. After surgery he used a 3-week nonweightbearing short leg cast and a 3-week weightbearing short leg cast. Although 7 months passed after surgery, the fracture site did not achieve union and fell into atrophic nonunion. At 25 months after the initial symptoms and 7 months after surgery, we performed ESWT. The doses of shock waves were 2000 impulses at 24

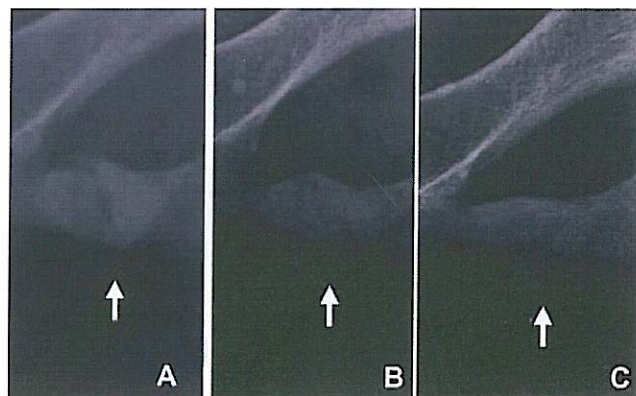


Figure 3. Case 3 (22-year-old female marathon runner). A, stress fracture of the inferior pubic ramus before extracorporeal shock wave therapy (ESWT); B, at 3 months after ESWT, bony union already achieved; C, at 12 months after ESWT, fusion is intact and developed.

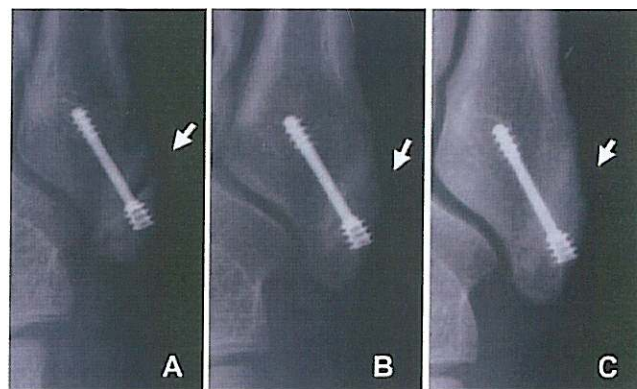


Figure 4. Case 4 (21-year-old male soccer player). A, stress fracture of the fifth metatarsal base before extracorporeal shock wave therapy (ESWT); B, at 2 months after ESWT, bony union already achieved; C, at 12 months after ESWT, fusion became more complete.

kV. After ESWT, we used a nonweightbearing short leg cast for 4 weeks. Radiographic consolidation was observed gradually on radiographs. The CT image showed consolidation and union at 3 months after ESWT. The player started jogging and was able to return to baseball completely 6 months after ESWT. At 12 months, after the internal fixation was removed, the bony union remained intact on radiographs. At 3 years after ESWT, he played baseball without difficulty, and the fusion was fully developed in the radiographs (Figures 5 and 6).

DISCUSSION

Since 1986, investigators have studied the effects of extracorporeal shock wave on bones.^{6,10,13,14} They reported that shock wave induces periosteal detachment and trabecular microfractures with hemorrhages, in turn stimulating fracture healing. Recently, a few experimental studies have reported

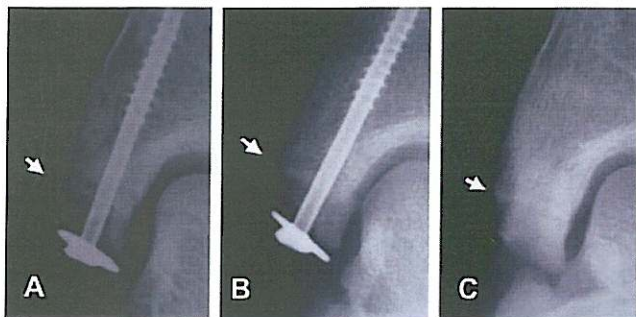


Figure 5. Case 5 (17-year-old male baseball player). A, stress fracture of the medial malleolus of the left ankle before extracorporeal shock wave therapy (ESWT); B, at 3 months after ESWT, consolidation is seen; C, at 12 months after ESWT, after internal fixation was removed, the bony union remained intact.

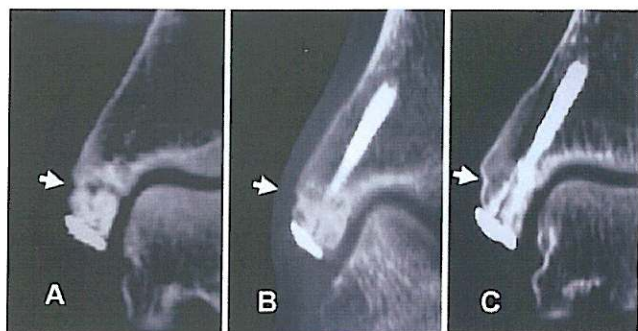


Figure 6. Case 5 (17-year-old male baseball player). The CT image of case 5. A, nonunion before extracorporeal shock wave therapy (ESWT); B, at 3 months after ESWT, bony union already achieved; C, at 6 months after ESWT, fusion became more complete.

that shock wave induces angiogenesis-related growth factors including endothelial nitric oxide synthase, vessel endothelial growth factor, and proliferating cell nuclear antigen, and then stimulates neovascularization, which improves blood supply and increases cell proliferation.^{17,28} These clinical and basic data could suggest not only healing acceleration but also healing regeneration effects of ESWT.

Clinically, several case series studies on ESWT for pseudarthrosis have been reported.^{9,11,23-25,27} Their success rate is in the range of 62% to 91%, and no complications have been reported except for slight hematoma. There are few clinical reports on ESWT for stress fractures. In the field of thoroughbred racehorses, ESWT has become a new treatment for stress fractures.^{4,19}

Our clinical results suggest that ESWT is effective for resistant stress fractures in athletes. Radiographic union developed in all cases. The average duration until observed development of bony union was 2.9 months. The time until complete return to sports averaged 4 months. No complications or recurrences were observed in any of the 5 cases. Matheson et al¹⁶ related that mean recovery time to sports

was 12.8 weeks for 320 stress fractures. Considering the difficulty of our intractable cases, our clinical outcomes are encouraging.

Cases 1 and 2 were stress fractures of the anterior cortex of the tibial midshaft. Midanterior tibial stress fractures are less common but more resistant to nonoperative treatment.^{3,8,21} They have often been treated with intramedullary nailing for an early return to sports. But we cannot disregard surgical stresses and postoperative complications in athletes.^{3,15,26} Especially in young athletes with open growth plates (as in case 2), intramedullary nailing is contraindicated. Progress after ESWT was good, so ESWT can be an effective alternative treatment for this type of stress fracture. Extracorporeal shock wave therapy may become the first choice for resistant midanterior tibial stress fractures among young athletes.

Pubic ramus stress fracture (as in case 3) is a common injury of long-distance runners. In principle, it can be restored conservatively,^{7,18} but occasionally intractable cases occur.²⁰ However, evidence supporting surgical treatment cannot be found. The best treatment for recalcitrant stress fractures of the pubic ramus is not clear.

Cases 4 and 5 were postoperative nonunions of stress fracture. These cases show that an existing internal fixation device is no contraindication for ESWT. After surgical treatment, these players' fracture sites developed into pseudarthrosis. If the affected part is unstable, it needs adequate immobilization after ESWT.^{23,25} For that reason, these 2 cases used nonweightbearing short leg casts after ESWT. We need to consider this additional treatment in the result. However, these postoperative pseudarthroses were improved only after ESWT. In particular, in case 5 there was advanced atrophic nonunion and a further operation was difficult. Extracorporeal shock wave therapy led to significant restoration in case 5.

Recently, low-intensity pulsed ultrasound has been widely used for noninvasive treatment of pseudarthrosis. Low-intensity pulsed ultrasound does not require anesthesia, which is a major disadvantage of ESWT. However, ESWT generally requires only a single treatment, and it can be used when the athlete has internal fixation devices or deep treatment areas. In addition, it is possible to judge whether ESWT was successful within several weeks to 2 months after treatment in most cases. It is particularly important for athletes to estimate the time of their return, so that even if ESWT is unsuccessful, other options can be considered.

CONCLUSION

These reports demonstrate that ESWT is a noninvasive and effective method to treat intractable stress fracture in athletes. Furthermore, in young athletes with growth plates (like case 2) and in cases of postoperative pseudarthroses (like cases 4 and 5), there are indications that this treatment can be promising. We require additional basic and clinical studies to understand the effectiveness of ESWT and further studies to determine optimal energy density levels and impulse rates. Nevertheless, when appropriately used, ESWT can be a safe

and effective treatment for stress fractures, especially in resistant cases.

ACKNOWLEDGMENT

The treatment was performed at the Shonan Kamakura General Hospital. We gratefully acknowledge the invaluable contributions of Akiyoshi Saito, MD, PhD, Tatsuya Kubomura, MD, Yasushi Onuma, MD, and Jon Nyerges.

REFERENCES

- Benazzo F, Mosconi M, Beccarisi G, Galli U. Use of capacitive coupled electric fields in stress fractures in athletes. *Clin Orthop Relat Res*. 1995;310:145-149.
- Brand JC Jr, Brindle T, Nyland J, Caborn DN, Johnson DL. Does pulsed low intensity ultrasound allow early return to normal activities when treating stress fractures? A review of one tarsal navicular and eight tibial stress fractures. *Iowa Orthop J*. 1999;19:26-30.
- Chang PS, Harris RM. Intramedullary nailing for chronic tibial stress fractures. A review of five cases. *Am J Sports Med*. 1996;24:688-692.
- Da Costa Gomez TM, Radtke CL, Kalscheur VL, et al. Effect of focused and radial extracorporeal shock wave therapy on equine bone micro-damage. *Vet Surg*. 2004;33(1):49-55.
- DeLee JC, Evans JP, Julian J. Stress fracture of the fifth metatarsal. *Am J Sports Med*. 1983;11:349-353.
- Delius M, Draenert K, Al Diek Y, Draenert Y. Biological effects of shock waves: in vivo effect of high energy pulses on rabbit bone. *Ultrasound Med Biol*. 1995;21:1219-1225.
- Eren OT, Holtby R. Straddle pelvic stress fracture in a female marathon runner: a case report. *Am J Sports Med*. 1998;26:850-851.
- Green NE, Rogers RA, Lipscomb AB. Nonunions of stress fractures of the tibia. *Am J Sports Med*. 1985;13:171-176.
- Haist J. Die osteorestitution via stoßwellenanwendung. Eine neue möglichkeit zur theraoie der gestorten knochernen konsolidierung. In: Chaussy C, Eisenberger F, Jochum D, Wilbert D, eds. *Die Stoßwelle-Forschung und Klinik*. Tübingen, Germany: Attempto;1995:157-161.
- Haupt G, Haupt A, Ekkernkamp A, Gerety B, Chvaplil M. Influence of shock waves on fracture healing. *Urology*. 1992;39:529-532.
- Haupt G, Katzmeier P. Anwendung der hochenergetischen extracorporalen stoßwellentherapie bei pseudarthrosen, Tendinosis calcanea der schulter und ansatztendinopathien (Fersensporn, Epicondylitis). In: Chaussy C, Eisenberger F, Jochum D, Wilbert D, eds. *Die Stoßwelle-Forschung und Klinik*. Tübingen, Germany: Attempto; 1995:143-146.
- Hulkko A, Orava S. Stress fractures in athletes. *Int J Sports Med*. 1987;8:221-226.
- Johannes EJ, Kaulesar Sukul DM, Matura E. High-energy shock waves for the treatment of nonunions: an experiment on dogs. *J Surg Res*. 1994;57:246-252.
- Kaulesar Sukul DM, Johannes EJ, Pierik EG, van Eijck GJ, Kristelijn MJ. The effect of high energy shock waves focused on cortical bone: an in vitro study. *J Surg Res*. 1993;54:46-51.
- Martinez SF, Murphy GA. Tibial stress fracture in a male ballet dancer: a case report. *Am J Sports Med*. 2005;33:124-130.
- Matheson GO, Clement DB, McKenzie DC, Taunton JE, Lloyd-Smith DR, MacIntyre JG. Stress fractures in athletes: a study of 320 cases. *Am J Sports Med*. 1987;15:46-58.
- Nishida T, Shimokawa H, Oi K, et al. Extracorporeal cardiac shock wave therapy markedly ameliorates ischemia-induced myocardial dysfunction in pigs in vivo. *Circulation*. 2004;110:3055-3061.
- Noakes TD, Smith JA, Lindenberg G, Wills CE. Pelvic stress fractures in long distance runners. *Am J Sports Med*. 1985;13:120-123.
- Palmar SE. Treatment of dorsal metacarpal disease in the thoroughbred racehorse with radial extracorporeal shock wave therapy. *Proc Am Assoc Equine Practnr*. 2002;48:318-321.
- Pavlov H, Nelson TL, Warren RF, Torg JS, Burstein AH. Stress fractures of the pubic ramus. A report of twelve cases. *J Bone Joint Surg Am*. 1982;64:1020-1025.
- Rettig AC, Shelbourne KD, McCarroll JR, Bisesi M, Watts J. The natural history and treatment of delayed union stress fractures of the anterior cortex of the tibia. *Am J Sports Med*. 1988;16:250-255.
- Rue JP, Armstrong DW III, Frassica FJ, Deafenbaugh M, Wilckens JH. The effect of pulsed ultrasound in the treatment of tibial stress fractures. *Orthopedics*. 2004;27:1192-1195.
- Schaden W, Fischer A, Sailler A. Extracorporeal shock wave therapy of nonunion or delayed osseous union. *Clin Orthop Relat Res*. 2001;387:90-94.
- Schleberger R, Senge T. Non-invasive treatment of long-bone pseudarthrosis by shock waves (ESWL). *Arch Orthop Trauma Surg*. 1992;111:224-227.
- Valchanou VD, Michailov P. High energy shock waves in the treatment of delayed and nonunion of fractures. *Int Orthop*. 1991;15:181-184.
- Varnier KE, Younas SA, Lintner DM, Marymont JV. Chronic anterior midtibial stress fractures in athletes treated with reamed intramedullary nailing. *Am J Sports Med*. 2005;33:1071-1076.
- Vogel J, Rompe JD, Hopf C, Heine J, Burger R. Die hochenergetische extracorporale stoßwellentherapie (ESWT) in der behandlung von pseudarthrosen. *Z Orthop Ihre Grenzgeb*. 1997;135:145-149.
- Wang CJ. An overview of shock wave therapy in musculoskeletal disorders. *Chang Gung Med J*. 2003;26:220-232.